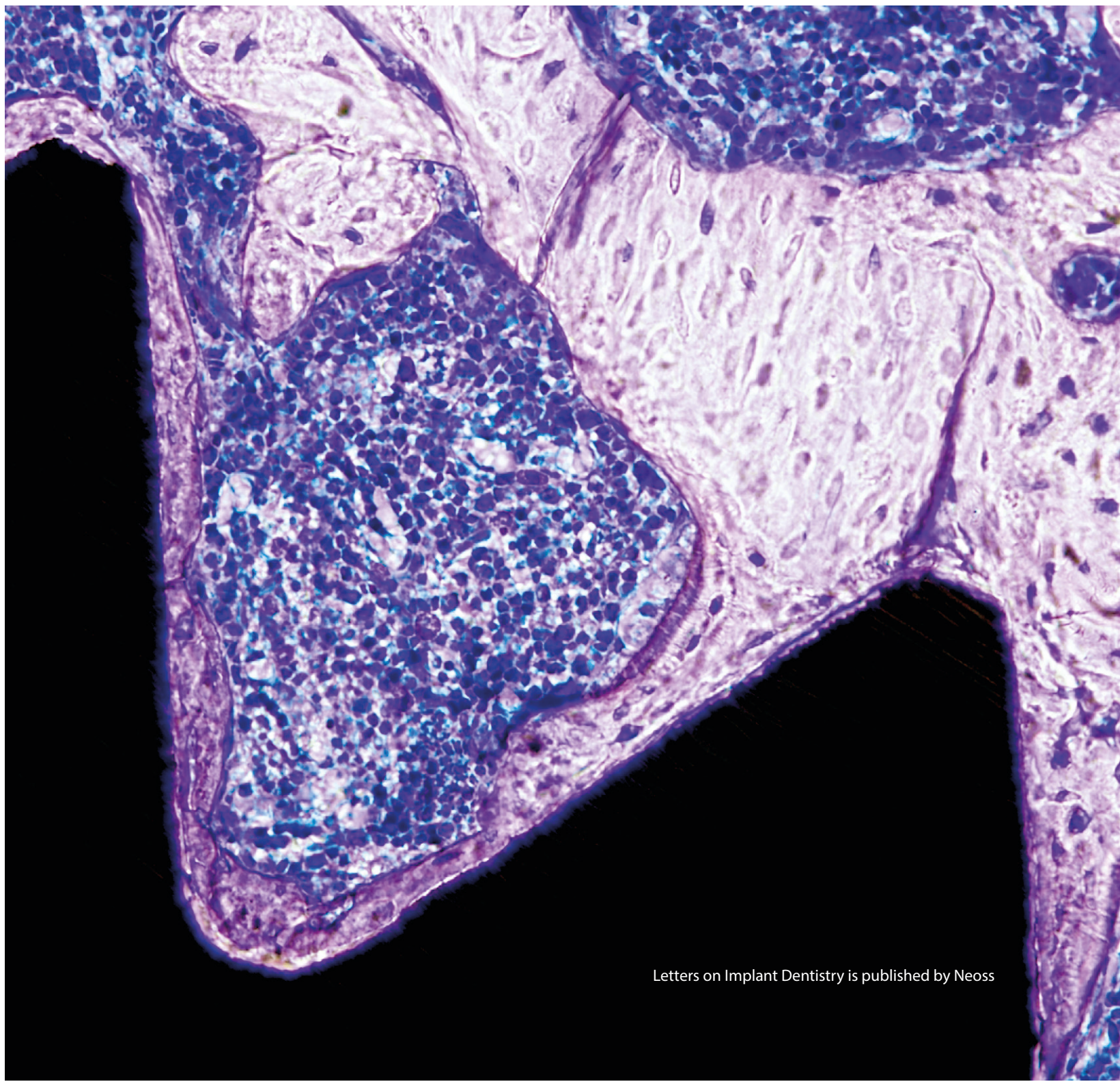


Volume 2. June 2022

# LETTERS ON IMPLANT DENTISTRY

Short communications on basic research, clinical techniques and outcomes related to Neoss treatment solutions



Letters on Implant Dentistry is published by Neoss

**Cover image:**

*Histological section of a ProActive implant implanted in rat tibia. The newly formed bone along the implant surface shows a perfect example of contact osteogenesis, the process where the implant surface induces bone formation along the surface. Read more on page 12.*

## Welcome to the Neoss research community

I hope you will enjoy and learn from this volume of Letters on Implant Dentistry that represents a sample of the research made in collaboration with clinicians and scientists.

At Neoss we encourage and support clinically relevant research on our products with the aim to communicate the outcomes to our customers in a straightforward way. In other words, research performed with intelligent simplicity.

If you would like to be part of the evergrowing Neoss research community, by documenting cases, performing studies, or contributing with your work in future editions of Letters on Implant Dentistry, please contact us!

**Dr. Herman Sahlin**

Research Director, Neoss  
research@neoss.com

## Twenty years with Neoss – Science and proven experience

It is our great pleasure to present yet another volume of Letters on Implant Dentistry, this time published in conjunction with the Integrate meeting in Gothenburg, Sweden, to celebrate the first twenty years with the Neoss implant system. It was in Gothenburg where modern implant dentistry was born thanks to the pioneering work of Professor P-I Brånemark and his interdisciplinary research group.

The Neoss implant system has been developed in the same unique academic and industrial environment with focus on innovative solutions to make implant dentistry less complicated and more predictable. The Neoss implant system has been used for almost twenty years in daily clinical work by an increasing number of devoted clinicians around the world.

Science and proven experience are the cornerstones of sound dental and medical clinical practice. Although the work in patients is the ultimate test for any product or clinical technique, scientific studies are needed to critically scrutinize and confirm what has been found from clinical experience. Hence, a clinical study is the top of a pyramid representing vast practical experience from a particular treatment modality. Input from innovators, university scientists and industry are all important catalysers for the developmental process, and it is therefore vital for all involved parties to meet, communicate, share, and debate experiences and ideas.

Letters on Implant Dentistry contains short communications related to Neoss products and treatment solutions. For instance, the technique behind the creation of the ProActive surface and its effects on bone integration is discussed and a systematic review of all clinical studies on Neoss ProActive implants is presented. In addition, the reader will find several short multi- and single-center retrospective studies on the use of ProActive implants on different indications, such as single tooth replacements in gaps with or without sufficient bone volumes, immediate loading of full-arch bridges in total extraction cases and rehabilitation of the atrophied posterior maxilla with a sinus membrane elevation technique. One critical review concerns the idea that peri-implantitis is a major threat to the survival of dental implants. Some readers will for sure find the conclusions provocative but at the same time comforting. Finally, two papers are presenting experimental and clinical data on the NeoGen PTFE membrane used for guided bone regeneration.

**Prof. Lars Sennerby**

Editor-in-Chief

**Prof. Christer Dahlin**

Co-Editor

# Table of contents

## IMPLANTS | PRE-CLINICAL RESEARCH

<b>The ProActive implant surface – innovative engineering and surface technology leading to fast implant integration and predictable clinical results</b>	<b>6</b>
Fredrik Engman, Lars Sennerby	
<b>Osseointegration of ProActive implants. A histological comparative study</b>	<b>12</b>
Marcel Kunrath, Hanna Aludden, Birgitta Norlindh, Lena Emanuelsson, Christer Dahlin	
<b>The Neoss ProActive Edge implant – biomechanical aspects</b>	<b>15</b>
Lars Sennerby, Matteo Turra, Anders Petersson	

## IMPLANTS | CLINICAL RESEARCH

<b>Implant survival, bone remodeling and implant stability of Neoss ProActive implants. A systematic review of the literature</b>	<b>18</b>
Herman Sahlin, Malin Bjursten Brailsford	
<b>The Neoss ProActive Edge implant. Preliminary clinical experiences and results</b>	<b>25</b>
Matteo Turra, Peter Andersson, Damiano Verrocchi, Lars Sennerby	
<b>Factors influencing 10-year survival of Neoss ProActive implants. A retrospective survey</b>	<b>29</b>
Lars Sennerby, Luca Pagliani, Stefano Volpe, Peter Andersson, Damiano Verrocchi	
<b>Extraction of remaining teeth and same-day load of Neoss ProActive implants with a provisional full-arch fixed bridge</b>	<b>33</b>
Pierluigi Coli, Lars Sennerby	

<b>Lateral sinus membrane elevation for graftless bone augmentation at Neoss implants in the atrophied posterior maxilla. A retrospective multi-centre survey</b>	<b>39</b>
Luca Pagliani, Roberto Romano, Nicola Sgaramella, Axel Andersson, Peter Andersson, Damiano Verrocchi, Lars Sennerby, Stefan Lundgren	
<b>Short implants for single tooth replacement in limited bone volumes in the posterior maxilla</b>	<b>45</b>
Stefano Volpe, Michele Di Girolamo, Peter Andersson, Damiano Verrocchi, Lars Sennerby	
<b>Single tooth restorations on Neoss ProActive Straight implants in healed sites and extraction sockets. A retrospective survival analysis</b>	<b>49</b>
Pierluigi Coli, Lars Sennerby	
<b>Peri-implantitis. A short and critical review</b>	<b>53</b>
Pierluigi Coli, Kevin Lochhead, Lars Sennerby	
 <b>MEMBRANES   PRE-CLINICAL AND CLINICAL RESEARCH</b>	
<b>NeoGen PTFE membranes. A review of the published clinical and pre-clinical evidence</b>	<b>57</b>
Herman Sahlin, Christer Dahlin	
<b>Vertical and horizontal guided bone regeneration (GBR) using a Ti-reinforced non-resorbable e-PTFE membrane and simultaneous implant placement. A retrospective study</b>	<b>62</b>
Nicolas Hassfurth, Norbert Hassfurth	

# The ProActive implant surface – innovative engineering and surface technology leading to fast implant integration and predictable clinical results

Fredrik Engman<sup>1</sup>, Lars Sennerby<sup>2</sup>

<sup>1</sup> Neoss, Gothenburg, Sweden

<sup>2</sup> Clinica Feltre, Feltre, Italy

*This article describes the innovative and unique techniques behind the super-hydrophilic ProActive surface. The biological consequences and effects of surface modification on implant integration are discussed*

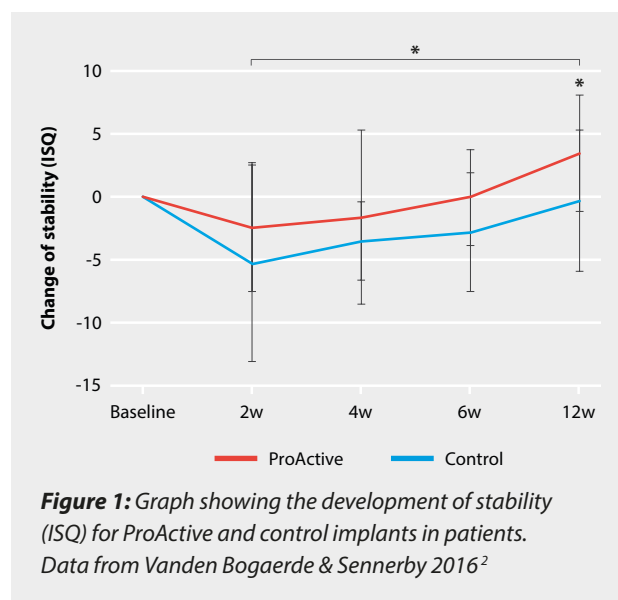
## INTRODUCTION

The use of osseointegrated dental implants is a highly successful biomechanical and biological treatment concept for replacement of missing teeth. The key to a successful outcome is to achieve and maintain or even increase mechanical stability (primary stability) during the healing process until osseointegration has been established (secondary stability).<sup>1</sup> The level of primary stability after surgery is mainly determined by bone density and implant design, whereas the implant surface properties influence the secondary stability. Hence, both primary and secondary stability can be optimized by implant design and surface technology. For instance, the dip of stability which has been demonstrated to occur after implant insertion can be minimized,<sup>2</sup> or even eliminated (Figure 1).<sup>3</sup>


## SURFACE PROPERTIES AND OSSEOINTEGRATION

### Surface roughness

Clinical and experimental studies have shown that moderately rough implant surfaces facilitate implant integration with bone and improve the clinical outcomes of implant treatment.<sup>4–5</sup> From an engineering point of view, there are several possible underlying factors why biological and clinical advantages are seen. The modified surfaces are



normally sharper and mechanically create a higher friction and retention than a machined surface, thus increasing the primary stability (Figure 2). There is also evidence that these sharp features create bone debris as the implant is inserted and that the debris act as a nucleus for new bone formation.<sup>6</sup> As discussed below, also design features as furrows may facilitate bone formation at the implant surface.<sup>7</sup>



**Figure 2:** SEM images of a number of commercially available dental implant surfaces:

(A) ProActive, Neoss,  
(B) SLActive, Straumann,  
(C) TiUnite, Nobel Biocare,  
(D) TiOblast, Dentsply Implants.

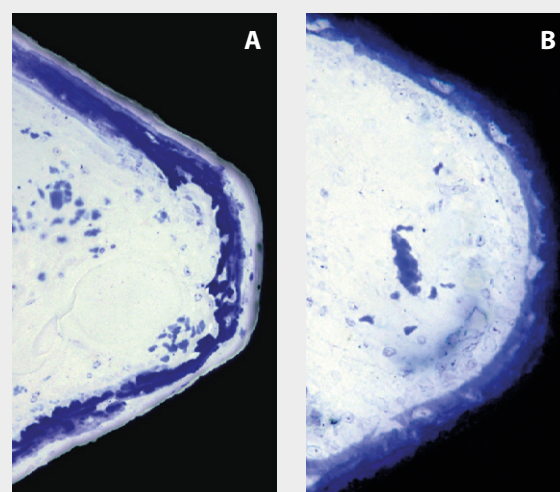
#### Hydrophilicity

The importance of implant surface cleanliness was recognized already in the early days of biomaterials science and osseointegration.<sup>8</sup> In recent years, the significance of hydrophilic properties to enhance the early biological healing process has been highlighted in the scientific literature.<sup>9</sup> A precondition for achieving a hydrophilic surface is that the underlying surface is ultraclean with minimal carbon content. Manufacturing, storage, packaging, and handling all contribute to the surface contamination of a dental implant. Carbon adsorption reduces surface energy and wettability and, thereby possibly impairing healing and implant integration. Typically, the implant needs to be immersed in a liquid as part of the packaging to maintain the hydrophilicity from the time of manufacture to clinical use. This leads to more complex packaging containers and additional costs.

#### Biological aspects

The surgical trauma when preparing an implant site induces a repair process, which for a successful implant results in bone integration, i.e. new bone formation and remodelling at the bone-implant interface.<sup>10</sup> Research has shown that different surface topographies may result in different integration patterns and that moderately rough surfaces are superior to smooth surface topographies in this respect.<sup>11–13</sup> In brief, it seems like the latter are integrated through a contact osteogenesis pathway, while the former is integrated through distance osteogenesis. This means that osteoblasts

use the moderately rough surface as a substrate and form new bone along and from the surface and towards the adjacent tissues (Figure 3). Furthermore, the bone condensation over the surface can be further facilitated if the surface has features such as furrows.<sup>7</sup> Although, the effect of chemical treatment is difficult to separate from that of surface topography in experimental and clinical research, in vitro studies using cell cultures have demonstrated biological advantages with hydrophilicity.<sup>9</sup> Studies on hydrophilic moderately rough implants have shown excellent bone tissue response and clinical results.<sup>9</sup>



**Figure 3:** Light micrographs showing (A) distance osteogenesis and (B) contact osteogenesis

### THE NEOSS PROACTIVE SURFACE

The Neoss ProActive surface was developed 15 years ago. Through a series of processes, an osteoconductive and super-hydrophilic implant surface with different roughness on collar and threads is formed. The surface is characterized by a dual surface roughness to optimize biological functions: The collar has a surface roughness with an Sa-value comparable to a polished surface ( $0.2–0.4\mu\text{m}$ ), while the micro- and macro-roughened threaded portion have an Sa-value around  $1\mu\text{m}$  (Table 1). This addresses the need to provide an osteoconductive surface during healing but also to minimize plaque adhesion in regions where the implant can be exposed to the oral environment after long term function.

The ProActive surface is manufactured using the following steps:

1. Blasting – to create the surface macro-roughness
2. Etching – to create the surface micro-roughness
3. Treatment with hydrated magnesium ions to make the surface super-hydrophilic.

#### *Blasting – creating the macro-roughness*

After machining and cleaning, the Neoss ProActive implant threads are carefully blasted with a process that leaves no chemical residue on the surface and creates a macro-roughness while maintaining the self-cutting features of the implant. The collar is not blasted, resulting in the dual surface roughness.

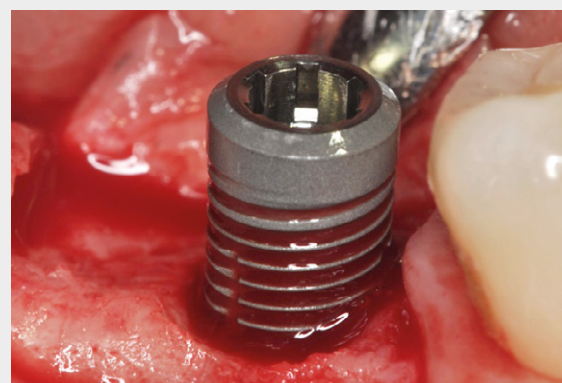
#### *Etching – creating the micro-roughness*

After blasting, the complete implant – thread and collar – is etched to receive a superimposed micro-roughened surface. At this point the actual Neoss ProActive surface has been created.

The ProActive etching process generates a honeycomb microstructure with fine ridges and small pits at sub-micron level (Figure 2A). Compared to other implant surfaces, the ProActive micro morphology structure is similar

Parameter	Sa ( $\mu\text{m}$ )	Sdr (%)
ProActive	Collar: $0.3–0.4$ Thread: $0.8–1.0$	Collar: 50 Thread: 103
SLActive	1.75	143
TiUnite	1.1	37
OsseoSpeed	1.4	37

**Table 1:** Surface roughness – a comparison of Sa and Sdr values for a number of commercially available dental implant surfaces: (A) ProActive, Neoss, (B) SLActive, Straumann, (C) TiUnite, Nobel Biocare, (D) Osseospeed, Dentsply Implants.




**Figure 4:** Surgical placement of a ProActive implant visually demonstrating the hydrophilic properties through the blood wicking up the threads. The shiny implant collar is typical for the solid water surface.

to SLActive (Straumann) while completely different to TiUnite (Nobel Biocare) and OsseoSpeed (Dentsply Sirona Implants) as demonstrated by SEM (Figure 2).

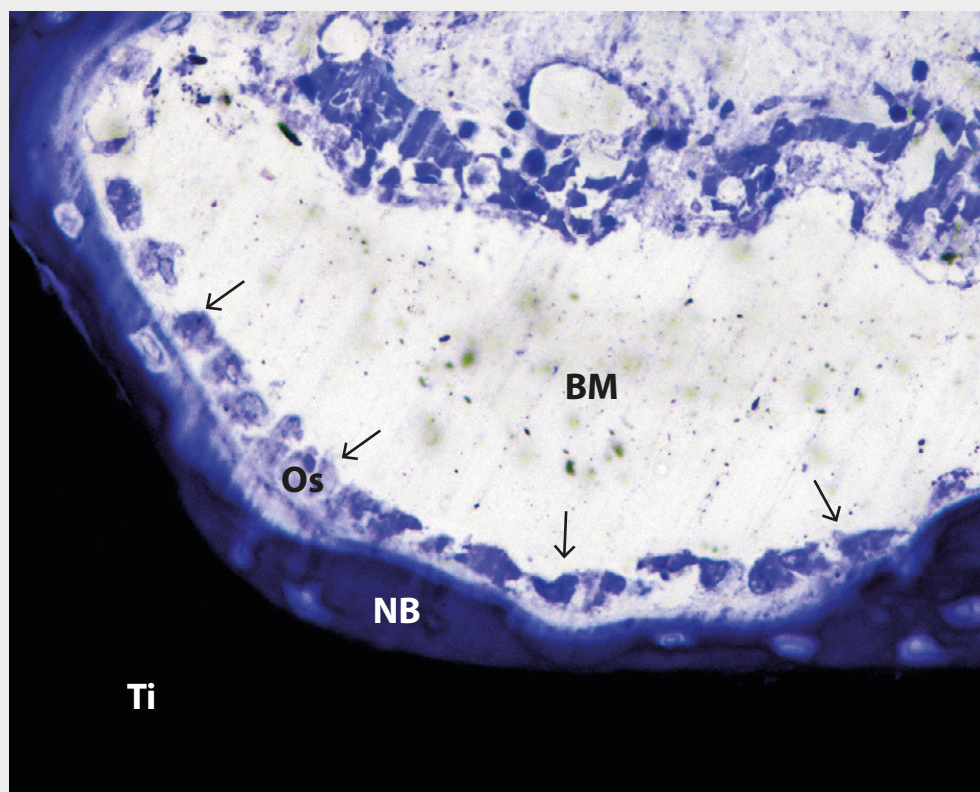
The ProActive surface has been designed with lower surface roughness than most competitor surfaces (Table 1).<sup>4</sup> The design rationale behind the lower roughness is to achieve a balance between initial stability and long-term predictability by minimizing the retention of plaque that rougher surfaces can exhibit.<sup>14</sup>

#### *Super-hydrophilicity treatment*

After etching, the implants are subjected to the superhydrophilicity treatment which enables the implant to achieve an exceptionally high level of wettability without altering the blasted and etched surface (Figure 4).

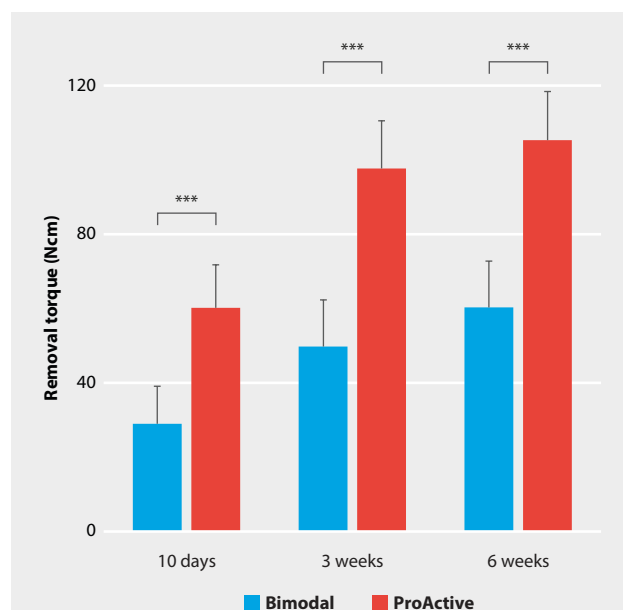


**Figure 5:** Hydrophilic properties were examined by a simple drop test on different dental implant surfaces: (A) ProActive, Neoss, (B) SLActive, Straumann, (C) TiUnite, Nobel Biocare, (D) Osseospeed, Dentsply Implants.



**Figure 6:** Light micrograph of the ProActive surface after 10 days of healing showing contact osteogenesis. New bone (NB) has been formed directly on the implant (Ti) surface. Active osteoblasts (arrows) followed by a layer osteoid (Os) can be seen. BM = bone marrow.

A thin layer of ultra-clean hydrated  $Mg^{2+}$  (magnesium) ions is deposited onto the surface. A hydrated  $Mg^{2+}$  ion is an  $Mg^{2+}$  ion that binds six water molecules. The hydrated ions create bonds with each other and the implant surface to form a stable solid-state water-rich film on the implant.

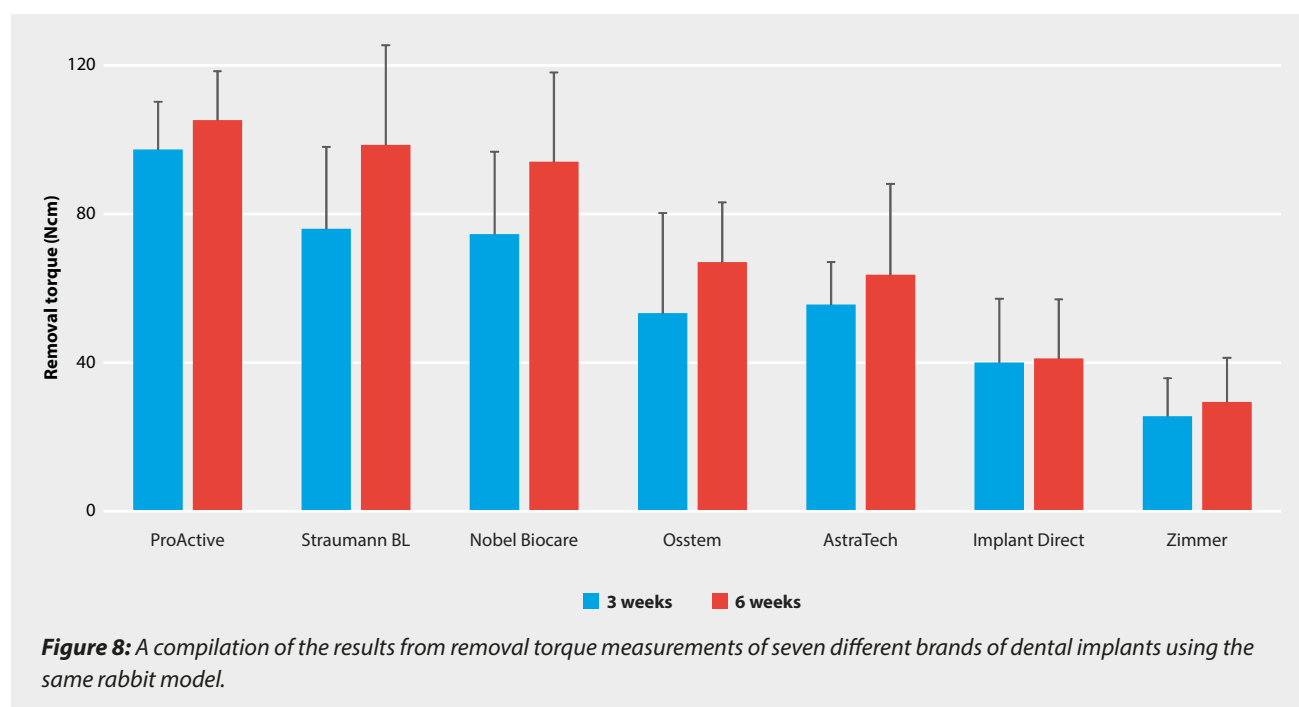


**Figure 7:** Results from removal torque measurements of Neoss Bimodal and ProActive implants after 10 days, 3 and 6 weeks. \*\*\* = Statistical significance ( $p \leq 0.001$ ).

The film has a solid, transparent, and glossy appearance similar to ice and are stable on the implant surface at temperatures as high as 60°C. This treatment is what makes the ProActive surface super-hydrophilic as demonstrated in surgical practice (Figure 4) and by the immeasurable low contact angle compared to other dental implant surfaces (Figure 5).

The  $Mg^{2+}$  ions used in the superhydrophilicity treatment are highly soluble which means that there is no  $Mg^{2+}$  bound to the implant surface once the implant is implanted.  $Mg^{2+}$  is abundant in the human body. It has also been shown to be an important substance for bone formation, but any direct correlation for ProActive still needs to be explored.<sup>15</sup> Even though the deposited water and  $Mg^{2+}$  ions are highly soluble, they are highly stable on the surface which enables the implants to be delivered in conventional packages. This eliminates the need for the implant to be packaged in a liquid solution like other hydrophilic implants. The ProActive production process uses non-contaminating blasting particles and ultra-clean water supply. In addition, the implant packages are made of glass. This maintains the low carbon content on the implant surface, thereby maximizing surface energy.

Compared to other dental implant surfaces with carbon levels in the 30–50% range,<sup>16</sup> the levels of surface contamination on the ProActive surface is very low with carbon levels



generally below 20% and minimal levels of the trace elements P, S, Ca and Cl (Table 2).<sup>17</sup> The data also shows that the ProActive super-hydrophilicity treatment does not leave any Mg<sup>2+</sup> remnants.

#### BONE TISSUE RESPONSES TO PROACTIVE IMPLANTS

Several experimental studies have been conducted to evaluate the integration and stability of Neoss ProActive and other implant types.<sup>18–20</sup> Histological analyses showed bone integration by contact osteogenesis for ProActive surfaces with typical bone formation directly on the implant surface (Figure 6). In comparison with a smooth control implant, ProActive showed a marked and significantly higher removal torque 10 days, 3 and 6 weeks after insertion in rabbit bone (Figure 7). The ProActive surface reached the same stability already after 10 days as the showed surface showed after 6 weeks.

When comparing removal torque tests of various commercial brands of dental implants (Figure 8), it was obvious that the blasted and acid etched and hydrophilic implants (Neoss ProActive and Straumann SLActive) as well as oxidized implants (Nobel Biocare) showed higher torque values than the implants subjected to blasting only (Osstem, AstraTech, Implant Direct).<sup>20</sup> Although not statistically tested, the Neoss ProActive implant showed numerically higher removal torque values after three weeks when compared with the other brands. However, after six weeks both the Straumann SLActive and Nobel Biocare TiUnite surfaces showed similar high removal torque values as the Neoss ProActive surface.<sup>20</sup>

#### CONCLUSION

The Neoss implant system includes a series of innovative implant designs with the ProActive super-hydrophilic surface, intended to offer high initial stability, rapid integration and predictable clinical results. Experimental studies have demonstrated that the Neoss ProActive surface provokes a swift and strong bone tissue response after surgical placement and performs better or similar as other brands of dental implants.<sup>20</sup> From a clinical point of view, excellent outcomes with high survival rates, minimal crestal bone loss and few cases of peri-implantitis) are seen in normal and challenging situations such as in immediate/early loading and sinus floor augmentation cases.<sup>21–25</sup>

#### REFERENCES

1. Sennerby L, Meredith N. Implant stability measurements using resonance frequency analysis: biological and biomechanical aspects and clinical implications. *Periodontol* 2000. 2008;47:51-66
2. Vanden Bogaerde L, Sennerby L. A Randomized Case-Series Study Comparing the Stability of Implant with Two Different Surfaces Placed in Fresh Extraction Sockets and Immediately Loaded. *Int J Dent*. 2016;8424931
3. Rosen PS, Meredith N, Reynolds MA. Case reports describing the “bump”: A new phenomenon in implant healing. *J Impl Adv Clin Dent*. 2010;2:27-37
4. Wennerberg A, Albrektsson T. On implant surfaces: a review of current knowledge and opinions. *Int J Oral Maxillofac Implants*. 2010;25:63-74
5. Jemt T. Implant Survival in the Edentulous Jaw: 30 Years of Experience. Part II: A Retro-Pro prospective Multivariate Regression Analysis Related to Treated Arch and Implant Surface Roughness. *Int J Prosthodont*. 2018;31:531-539

6. Bosshardt DD, Salvi GE, Huynh-Ba G, Ivanovski S, Donos N, Lang NP. The role of bone debris in early healing adjacent to hydrophilic and hydrophobic implant surfaces in man. *Clin Oral Implants Res.* 2011;22:357-364
7. Hall J, Miranda-Burgos P, Sennerby L. Stimulation of directed bone growth at oxidized titanium implants by macroscopic grooves: an in vivo study. *Clin Implant Dent Relat Res.* 2005;7(S1):76-82
8. Kasemo B, Lausmaa J. Biomaterial and implant surfaces: on the role of cleanliness, contamination, and preparation procedures. *J Biomed Mater Res.* 1988;22(A2 Suppl):145-158
9. Bosshardt DD, Chappuis V, Buser D. Osseointegration of titanium, titanium alloy and zirconia dental implants: current knowledge and open questions. *Periodontol 2000.* 2017;73:22-40
10. Sennerby L, Thomsen P, Ericson LE. Early tissue response to titanium implants inserted in rabbit cortical bone. Part I Light microscopic observations. *J Mater Sci Mater Med.* 1993;4:240-250
11. Davies JE. Mechanisms of endosseous integration. *Int J Prosthodont.* 1998;11:391-401
12. Zechner W, Tangl S, Fürst G, Tepper G, Thams U, Mailath G, Watzek G. Osseous healing characteristics of three different implant types. *Clin Oral Implants Res.* 2003;14:150-157
13. Burgos PM, Rasmusson L, Meirelles L, Sennerby L. Early bone tissue responses to turned and oxidized implants in the rabbit tibia. *Clin Implant Dent Relat Res.* 2008;10:181-190.
14. Doornewaard R, Christiaens V, De Bruyn H, Jacobsson M, Cosyn J, Vervaeke S, Jacquet W. Long-Term Effect of Surface Roughness and Patients' Factors on Crestal Bone Loss at Dental Implants. A Systematic Review and Meta-Analysis. *Clin Implant Dent Relat Res.* 2017;19:372-399
15. Charyeva O, Dakischew O, Sommer U, Heiss C, Schnettler R, Lips KS. Biocompatibility of magnesium implants in primary human reaming debris-derived cells stem cells in vitro. *J Orthop Traumatol.* 2016;17:63-73
16. Kang BS, Sul YT, Oh SJ, Lee HJ, Albrektsson T. XPS, AES and SEM analysis of recent dental implants. *Acta Biomater.* 2009;5:2222-2229
17. Neoss Internal Report. AES Analysis ProActive implants
18. Gottlow J, Barkarmo S, Sennerby L. An experimental comparison of two different clinically used implant designs and surfaces. *Clin Implant Dent Relat Res.* 2012;14(S1):e204-e212
19. Grossi-Oliveira GA, Antunes AA, Elias CN, Wennerberg A, Sennerby L, Salata LA. Early Osseointegration Events on Neoss® ProActive and Bimodal Implants: A Comparison of Different Surfaces in an Animal Model. *Clin Implant Dent Relat Res.* 2015;17:1060-1072
20. Sennerby L, Gottlow J, Gottlow J. Integration of Neoss ProActive implants in comparison with other brands of dental implants. *Letters Implant Dent.* 2017;1:7-10
21. Sahlin H, Bjursten Brailsford M. Implant survival, bone remodeling and implant stability of Neoss ProActive implants: a systematic review of the literature. *Letters Implant Dent.* 2022;2:18-24
22. Sennerby L, Pagliani L, Volpe S, Andersson P, Verrocchi D. Factors influencing 10-year survival of Neoss ProActive implants. A retrospective survey. *Letters Implant Dent.* 2022;2:29-32
23. Coli P, Sennrby L. Extraction of remaining dentition and same-day loading of Neoss ProActive implants with a provisiona full-arch bridge. *Letter Implant Dent.* 2022;2:33-38
24. Pagliani L, Romano R, Sgaramella N, Andersson A4, Andersson P, Verrocchi D, Sennerby L, Lundgren S. Lateral sinus membrane elevation for graftless bone augmebtation at Neoss implants in the atrophied posterior maxilla. A retrospective multi-centre survey. *Letter Implant Dent.* 2022;2:39-44
25. Volpe S, Di Girolamo M, Andersson P, Damiano Verrocchi D, Sennerby L. Short implants for single tothh replacements in limited bone volumes in the posterior maxilla. *Letters Impl Dent.* 2022;2:45-48

# Osseointegration of ProActive implants. A histological comparative study

Marcel Kunrath<sup>1</sup>, Hanna Aludden<sup>1</sup>, Birgitta Norlindh<sup>1</sup>, Lena Emanuelsson<sup>1</sup>,  
Christer Dahlin<sup>1,2</sup>

<sup>1</sup> Department of Biomaterials, Institute of Clinical Sciences, Sahlgrenska Academy, University of Gothenburg, Sweden

<sup>2</sup> Department of Oral, Maxillofacial Surgery and Research and Development, NU-Hospital Organisation, Trollhättan, Sweden

*This in vivo study evaluated osseointegration of the ProActive surface compared to a machined surface. The preliminary results showed a clear improvement of osseointegration parameters as modulated by the micro-texturing and hydrophilicity of the ProActive surface.*

## INTRODUCTION

Since the introduction of osseointegration for more than 55 years ago, different surface treatments have been intensely explored to improve bone healing and adhesion of bone to the implants.<sup>1,2</sup> Machined surfaces were used in the pioneer studies from Brånemark and co-workers, while more modern implant systems have rougher surfaces, aiming for improved osseointegration and mechanical stability.<sup>3,4</sup>

Currently, the combination of properties, such as roughness and hydrophilicity, has been proposed to promote a stronger and faster osseointegration.<sup>5,6</sup> Micro-texturing and super-hydrophilicity have been demonstrated to modulate the molecular expression of some bone-related markers for bone adhesion and bone growth in vitro, suggesting significant differences compared to machined surfaces.<sup>7</sup>

For that reason, this study was undertaken to compare the two different surfaces (machined and modified hydrophilic surfaces) using an in vivo model to verify the significance of these surface treatments.

## MATERIALS AND METHODS

Titanium screws (2 mm × 3.2 mm) were manufactured. One group of implants were used as machined and one group was surface modified according to the ProActive

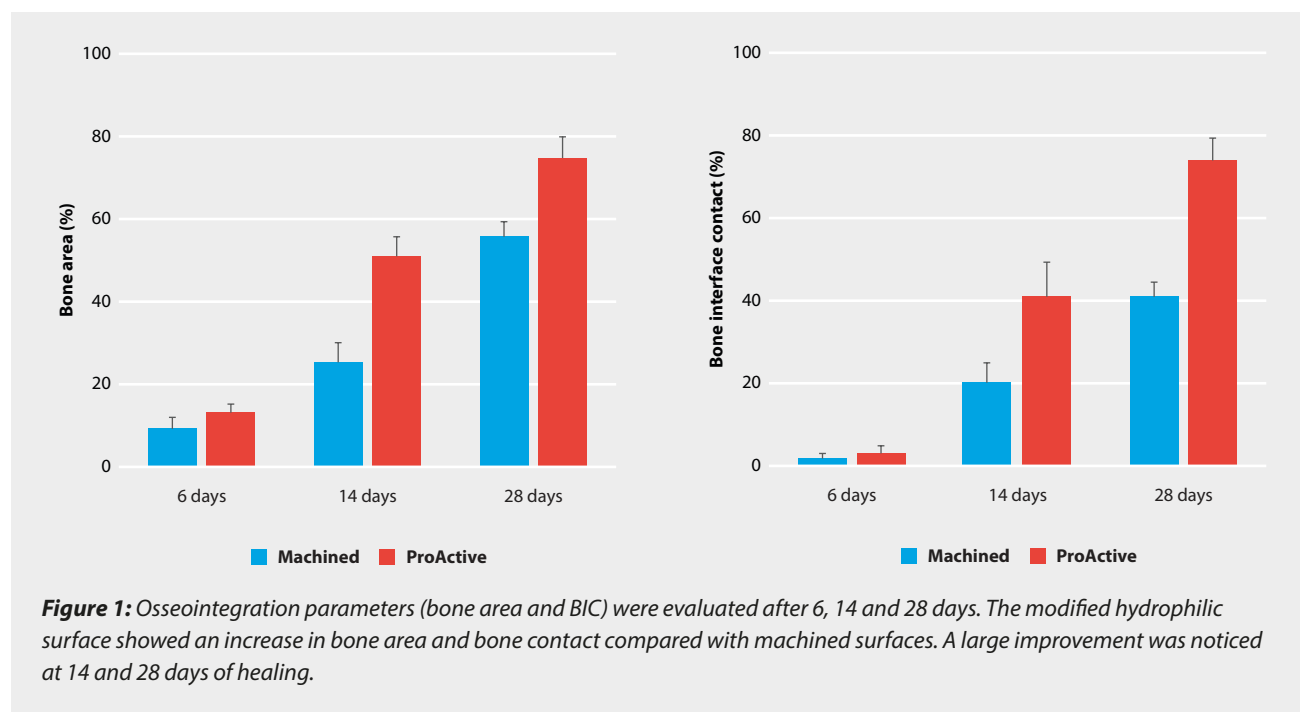
surface protocol (Neoss AB, Gothenburg, Sweden). One implant from each group was surgically inserted in each tibia of Sprague-Dawley rats. The animals were euthanized after 6, 14 or 28 days. The implants with surrounding bone were removed and prepared for histological ground sections, which were viewed in a light microscope for morphometrical analyzes. The area inside each thread occupied by bone (bone area (BA) in %) and the length of implant surface in contact with bone (bone-implant contact (BIC) in %) were measured.

## RESULTS AND DISCUSSION

Surface modification of the machined implants resulted in micro-texturing and differences of wettability properties. The machined implants were hydrophobic as indicated by a 105 degrees of contact angle, while the modified implants showed hydrophilicity and a 3 degrees of contact angle.

Regarding osseointegration, differences were seen after 14 days and 28 days in favor of the modified implant (Figure 1).

Although a cellular inflammatory response was evident, few signs of bone formation were seen after 6 days of healing. At 14 days, more BA and BIC were seen for the modified-hydrophilic surfaces. At 28 days, the BA and BIC parameters increased for both surfaces, however, it was



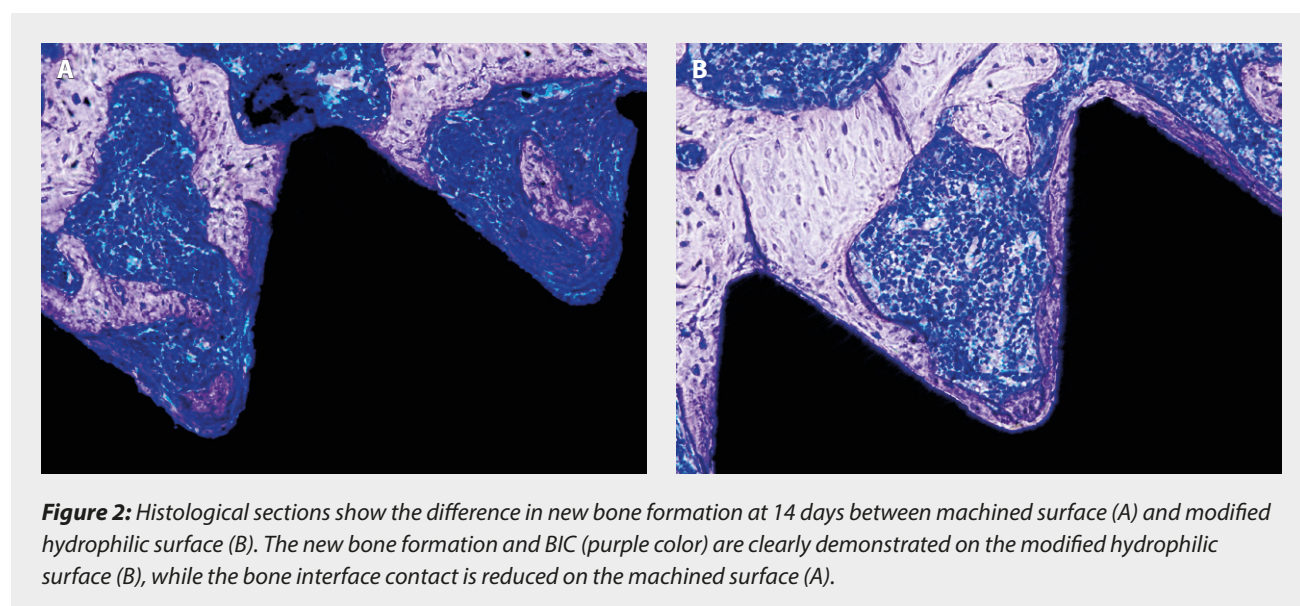
clearly revealed that the surface modified implants showed higher values. The analyses suggest that micro-texturing in combination with hydrophilicity induced more bone formation and bone-implant contacts than the machined surfaces (Figure 2).

## CONCLUSIONS

Within the limitations of this short investigation, our preliminary results demonstrated that microtexturing in combination with hydrophilicity resulted in a clear improvement of osseointegration parameters. Larger studies and clinical trials should be performed in order to corroborate these results and achieve clinical significance.

## REFERENCES

1. Brånemark PI, Adell R, Albrektsson T, Lekholm U, Lundkvist S, Rockler B. Osseointegrated titanium fixtures in the treatment of edentulousness. *Biomaterials*. 1983;4:25-28
2. Kunrath ME, Muradás TC, Penha N, Campos MM. Innovative surfaces and alloys for dental implants: What about biointerface-safety concerns?. *Dental Materials*. 2021;37:1447-1462
3. Albrektsson T, Wennerberg A. On osseointegration in relation to implant surfaces. *Clin Implant Dent Relat Res*. 2019;21:4-7
4. Lekholm U, Adell R, Lindhe J, Brånemark PI, Eriksson B, Rockler B, Yoneyama T. Marginal tissue reactions at osseointegrated titanium fixtures: (II) A cross-sectional retrospective study. *Int J Oral Maxillofac Surg*. 1986;15:53-61



5. Wennerberg A, Jimbo R, Stübinger S, Obrecht M, Dard M, Berner S. Nanostructures and hydrophilicity influence osseointegration: a biomechanical study in the rabbit tibia. *Clin Oral Implants Res.* 2014;25:1041-1050
6. Kunrath MF, Piassarollo dos Santos R, Dias de Oliveira S, Hubler R, Sesterheim P, Teixeira ER. Osteoblastic Cell Behavior and Early Bacterial Adhesion on Macro-, Micro-, and Nanostructured Titanium Surfaces for Biomedical Implant Applications. *Int J Oral Maxillofac Implants.* 2020;35:773-778
7. Siqueira R, Ferreira JA, Rizzante FAP, Moura GF, Mendonça DBS, de Magalhães D, Mendonça G. Hydrophilic titanium surface modulates early stages of osseointegration in osteoporosis. *J Periodont Res.* 2021;56:351-362

# The Neoss ProActive Edge implant – biomechanical aspects

Lars Sennerby<sup>1</sup>, Matteo Turra<sup>1</sup>, Anders Petersson<sup>2</sup>

<sup>1</sup> Clinica Feltre, Feltre, Italy

<sup>2</sup> Integration Diagnostics Sweden AB, Gothenburg, Sweden


*The present in vitro investigation evaluates the primary stability of the novel Neoss Edge implant in comparison with Neoss Straight, Neoss Tapered and two commercial implants with a similar design. In comparison with the latter, the Neoss Edge implant was found to achieve firmer or similar stability in a low density bone equivalent material.*

## INTRODUCTION

Many implant systems utilize tedious drilling protocols, which need to be adapted to different bone densities in order to ensure primary stability in soft bone and to avoid excessive compression of dense bone. The novel Neoss Edge implant was developed with the intention to speed up implant placement without jeopardizing primary implant stability and subsequent integration.<sup>1,2</sup> The original Neoss Straight design is slightly conical as it is machined with a one-degree positive tolerance.<sup>3</sup> This feature has a profound impact on the implant's stability after insertion, which is even more evident with increased tapering.<sup>4,5</sup> Any tapering leads to continuous lateral compression of the bone during placement, meaning that the entire implant body participates

in the development of stability. The potential risks of friction, overheating and ischemia due to tapering as foreseen by early implant designers have not been observed in any follow-up studies of Neoss Straight or Tapered implants.<sup>6</sup> One reason may be the addition of other design features such as double threads, long sharp cutting edges and relief planes to minimize friction.

The novel Neoss Edge implant is characterized by sharp threads, high thread pitch and marked tapering and that it can be placed with the use of one or two drills only. The aim of this study was to evaluate the primary stability of the Neoss Edge implant in comparison with the Neoss Straight and Tapered implants using an in vitro model. In addition, the Neoss Edge implant was compared with two commercially available and similar implant designs.<sup>7,8</sup>



**Figure 1:** The five implant designs evaluated in the study.

## MATERIAL & METHODS

Polyurethane (PU) blocks were used as bone equivalents in the study (15 pcf = low density and 20 pcf = normal density, Sawbones Europe AB, Malmö, Sweden).

In the first part of the experiment the three Neoss implant designs (Edge, Straight and Tapered, 4.5 × 13 mm) were compared in low and normal density PU blocks when using a standard drilling protocol (Figure 1).

In the second part of the study, the Neoss ProActive Edge 4.5 × 13 mm (Neoss, Gothenburg, Sweden) was compared with NobelActive 4.3 × 13 mm (Nobel Biocare, Zurich, Switzerland)<sup>7</sup> and BLX Roxolid 4.5 × 12 mm (Straumann,

	Final drill diameter (mm)		
	Reduced	Normal	Wide
<b>Neoss Edge</b>	3.9	3.4	3.0
<b>NobelActive</b>	4.2/3.8	3.6/3.2	2.8
<b>Straumann BLX</b>	4.2	3.7	2.8

**Table 1:** Final drill diameter used

Basel, Switzerland) (Figure 1).<sup>8</sup> The implants were placed in a soft PU block using three different drilling protocols according to the manufacturers' recommendations, resulting in either wide, normal or reduced osteotomy diameters (Table 1). The maximum peak insertion torque (IT) value (Ncm) (Elcomed, W&H, Austria) and implant stability quotient (ISQ) (PenguinRFA, IDSAB, Gothenburg, Sweden) was registered for each implant and situation.

The block was thereafter mounted in a specially designed rig for displacement measurements. A 10 N lateral force was applied to the top of the ISQ transducer and its movement measured in micrometers (Figure 2). The placement and measuring procedures were repeated three times for each implant and drilling protocol.

## RESULTS

### Comparison with Neoss implants

The three Neoss designs showed firm stability and no significant differences in the soft and normal bone equivalents when measured with RFA and displacement (Figure 3). However, significant differences were seen for IT values,

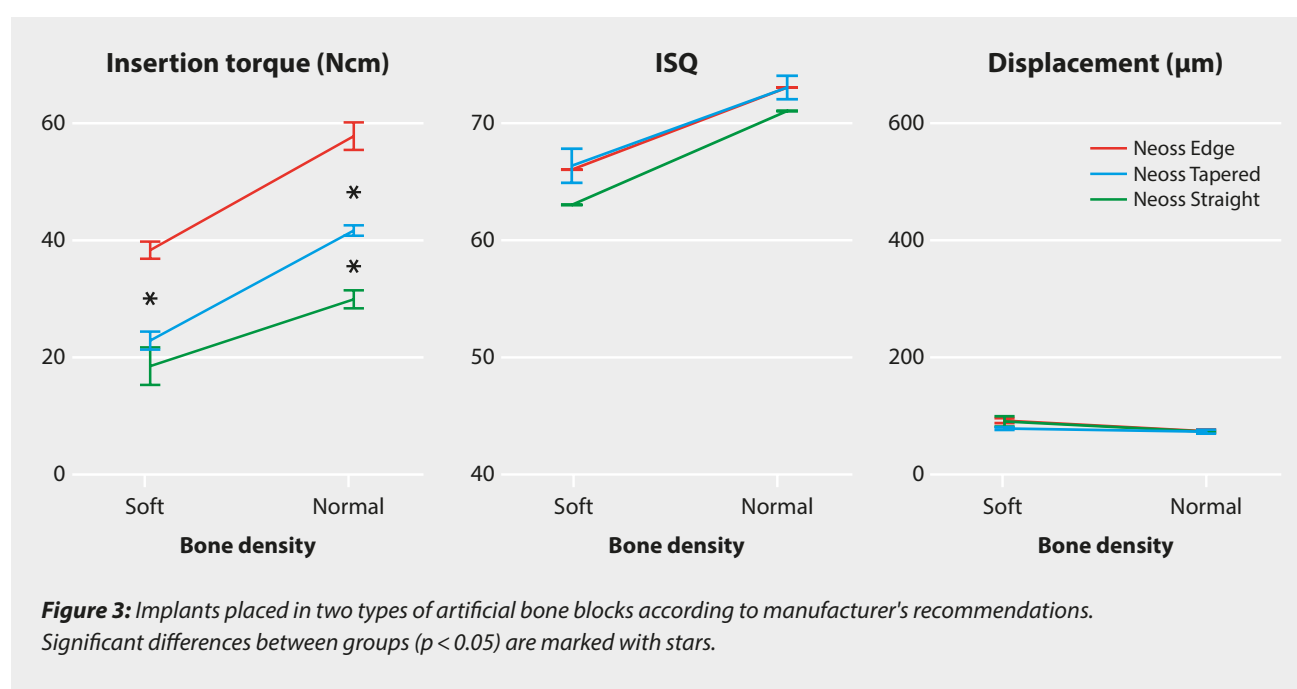


**Figure 2:** Neoss ProActive implants in a polyurethane block for displacement measurements. A lateral force of 10 N is applied with a metal rod (right) to a MultiPeg transducer attached to the implant (center) and the displacement measured by an electronic gauge (left).

where the Edge showed the highest values followed by Tapered and Straight implants in both densities, which also corresponded to the subjective feeling when placing the implants.

### Comparison with competitor implants

The three implant types showed an increase of insertion torque and ISQ values with reduced osteotomy diameter (Figure 4). The BLX implant showed (i) significantly lower insertion torque values, (ii) lower ISQ values for wide and reduced osteotomies as well as (iii) significantly more displacement in all osteotomies than Edge and NobelActive implants. The Neoss Edge implant showed significantly less displacement in the wide osteotomy compared to both NobelActive and BLX implants.



## DISCUSSION

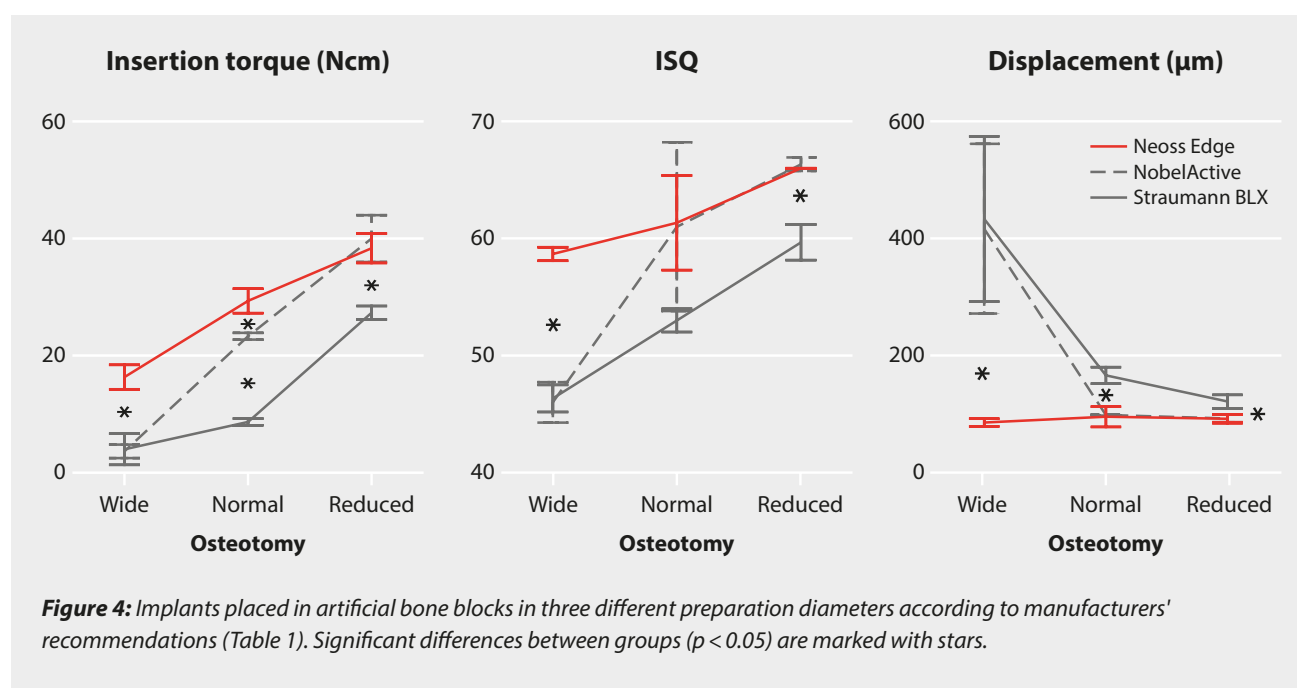
The present study showed that the Neoss Edge implant performed well when evaluated in an in vitro model. As expected, the registered IT values correlated with density and the degree of tapering: the Edge implant showed the highest values followed by Tapered and Straight implants in both densities. In spite of this, the ISQ and displacement measurements revealed a similar lateral stability of the three Neoss designs.

The comparative study indicated that the Neoss Edge implant gained sufficient primary stability in low density situations in comparison with the NobelActive and BLX implants, irrespective of drilling protocol. The differences seen between the implants, especially in the wide osteotomies, may be related to the different neck designs. The novel Edge implant has a wide and tapered head, which likely contributed to achieving stability by both lateral and axial clamping also in the wide osteotomy, while the NobelActive and BLX designs seems to rely on lateral clamping over the threaded part of the implant.

In conclusion, the Neoss Edge implant showed similar stability as the other Neoss designs but required higher insertion torque when placed in the PU blocks. In addition, the Edge implant showed better primary stability than two other similar and commercially available implants types.

## REFERENCES

1. Turra M, Petersson A, Sennerby L. Primary stability of three different aggressively threaded and tapered implants in low-density polyurethane. *Clin Oral Implants Res.* 2020;31(S20):60-61
2. Turra M, Andersson P, Verrocchi D, Sennerby L. A retrospective case series report on a novel aggressively threaded and tapered implant. *Clin Oral Implants Res.* 2020;31(S20):257
3. Engman F. The technology behind the ProActive surface. *Letters Implant Dent* 2017;1:11-14
4. O'Sullivan D, Sennerby L, Meredith N. Influence of implant taper on the primary and secondary stability of osseointegrated titanium implants. *Clin Oral Implants Res.* 2004;15:474-480
5. Sennerby L, Pagliani L, Petersson A, Verrocchi D, Volpe S, Andersson P. Two different implant designs and impact of related drilling protocols on primary stability in different bone densities: an in vitro comparison study. *Int J Oral Maxillofac Implants.* 2015;30:564-568
6. Sahlin H. Implant survival, bone remodeling and implant stability of Neoss implants: a systematic review of the literature. *Letters Implant Dent* 2017;1:15-20
7. Irinakis T, Wiebe C. Initial torque stability of a new bone condensing dental implant. A cohort study of 140 consecutively placed implants. *J Oral Implantol.* 2009;35:277-282
8. Francisco H, Finelle G, Bornert F, Sandgren R, Herber V, Warfving N, Pippenger BE. Peri-implant bone preservation of a novel, self-cutting, and fully tapered implant in the healed crestal ridge of minipigs: submerged vs. transgingival healing. *Clin Oral Investig.* 2021;25:6821-6832



# Implant survival, bone remodeling and implant stability of Neoss ProActive implants. A systematic review of the literature

Herman Sahlin<sup>1</sup>, Malin Bjursten Brailsford<sup>1</sup>

<sup>1</sup> Neoss, Gothenburg, Sweden

*This systematic review of the published literature on Neoss ProActive dental implants shows excellent long-term results with the ProActive implant system: High implant survival (CSR 98.0% after 10 years), minimal bone resorption (mean 0.7 mm after 5 years), and excellent primary and secondary stability in all types of bone.*

## INTRODUCTION

There are hundreds of different implant systems available on the market worldwide. The preference for one system over another could be based on anything from scientific evidence, clinical handling, inventory, and cost to preference of referring dentists.

However, the clinical safety and performance remains the only factor that ultimately defines the clinical suitability of an implant system.

The aim of this systematic review is to assess the current scientific evidence on Neoss ProActive implants regarding implant survival, bone remodeling and implant stability.

## MATERIALS AND METHODS

A bibliographical electronic research was carried out using PubMed/Medline and Google Scholar, identifying all published articles that report on clinical follow-up data on Neoss dental implants.

Electronic database searches were conducted in March 2022 and included all available data up to that point. The search term for the PubMed/MedLine search was “neoss OR (proactive AND dental implant)”. For the Google

Scholar search, the search term “neoss implant” was used. No restrictions were applied to the electronic searches. In addition to the online sources, the content of the Neoss internal literature database was screened.

To be eligible for further analysis, the publications should report at least one-year clinical follow-up data on Neoss implants.

The following exclusion criteria applied: less than 10 patients followed; no separate reporting on Neoss ProActive implants; review articles; language not English.


## RESULTS

The search yielded 832 articles. After the elimination of duplicates and the screening of titles and abstracts, full texts were retrieved for further screening. Twenty-five articles met the inclusion criteria and were included in the overall data analysis.<sup>1–25</sup>

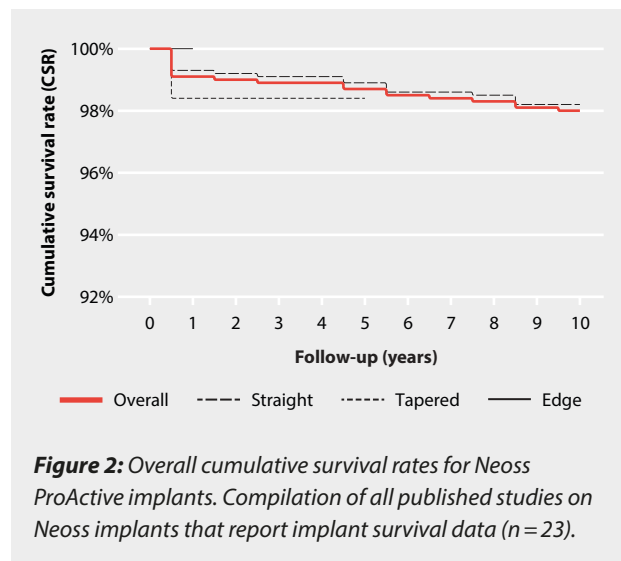
The analyzed articles (Table 1) present the combined clinical outcome of 6253 Neoss ProActive implants in 3372 patients, studied in 23 independent clinical studies with a follow-up time of 1 to 10 years (Figure 1). The combined data covers all major indications and treatment protocols.

Study	Study type	Topic	Implant type	Follow-up time	No. of patients	No. of implants	Survival rate (CSR)	Bone loss (mm)
Acham 2017 <sup>1</sup>	Randomized controlled trial	Immediate load, mandibular overdentures	ProActive	3 years	20	80	100%	–
Ali 2021 <sup>2</sup>	Randomized controlled trial	Immediate load, mandibular overdenture	ProActive	1 year	12	24	95.8%	0.8
Andreatta 2020 <sup>3</sup>	Retrospective case series	Immediate load, early delivery of definitive prosthesis	ProActive Tapered	1 year	25	48	100%	0.5
Coli 2019 <sup>4</sup>	Retrospective case series	Immediate placement, immediate load, full arch	ProActive Straight	2–5 years	30	156	97.3%	–
Coppe 2019 <sup>5</sup> Degasperri 2014 <sup>6</sup>	Retrospective case series	Early data on ProActive, 5 year follow-up	ProActive Straight	5 years	49	102	98.0%	0.9
Di Lallo 2014 <sup>7</sup>	Prospective controlled	Sinus lift	ProActive Straight	1 year	25	38	100%	–
Elsyad 2021 <sup>8</sup>	Randomized controlled trial	Immediate load, mandibular overdentures	ProActive	1 year	30	120	97.5%	0.8
Hassfurth 2021 <sup>9</sup>	Retrospective case series	Long-term results	ProActive Straight	10 years	721	1648	98.4%	–
Hassfurth 2020 <sup>10</sup>	Retrospective controlled	GBR treatment, PTFE membranes	ProActive Straight	1–9 years	1672	2399	97.7%	–
Maddalone 2020 <sup>11</sup>	Retrospective controlled	Tilted posterior implants	ProActive Straight	1–7 years	47	115	100%	–
Maryod 2022 <sup>12</sup>	Randomized controlled trial	Immediate load, mandibular overdentures	ProActive	1 year	8	32	96.9%	1.0
Rosen 2019 <sup>13</sup>	Retrospective case series	Implant treatment in patient >70 years	ProActive	1–9 years	207	387	96.5%	–
Rosen 2018 <sup>14</sup>	Retrospective case series	7 mm short implants	ProActive Straight	1–7 years	75	86	94.8%	–
Schütz 2020 <sup>15</sup>	Retrospective controlled	Tapered implants, GBR vs. non-GBR	ProActive Tapered	5 years	51	101	100%	0.7
Sennerby 2016 <sup>16</sup>	Retrospective case series	Immediate placement, early load, full-arch bridges	ProActive Straight, Tapered	1–6 years	43	258	96.5%	–
Shaheen 2020 <sup>17</sup>	Randomized controlled trial	Early load, mandibular overdenture	ProActive	1 year	10	40	97.5%	0.9
Shawky 2020 <sup>18</sup>	Randomized controlled trial	Immediate load, mandibular overdentures	ProActive	1 year	10	20	100%	0.8
Turra 2020 <sup>19</sup>	Retrospective case series	ProActive Edge implant	ProActive Edge	1 year	15	25	100%	0.5
van Thoor 2019 <sup>20</sup>	Retrospective case series	Sinus implant, one-visit sinus lift	ProActive 6.5 mm	1–5 years	128	192	99.0%	–
Vanden Bogaerde 2019 <sup>21</sup>	Retrospective case series	Immediate function, narrow implants in esthetic region	ProActive 3.25 mm	18 months	35	49	98.0%	0.7
Vanden Bogaerde 2016 <sup>22</sup>	Randomized controlled trial	Implant stability during healing	ProActive Straight	3 years	11	11	90.9%	0.6
Zumstein 2019 <sup>23</sup> Zumstein 2016 <sup>24</sup>	Retrospective controlled	GBR vs. non-GBR	ProActive Straight	5 years	51	159	98.7%	0.8
Zwaan 2016 <sup>25</sup>	Retrospective case series	Tapered implants	ProActive Tapered	1 year	97	163	96.9%	0.5

**Table 1:** Summary of the 23 identified studies, ordered alphabetically by first author.



**Figure 1:** Overview of studies.



Time interval	Implants	Failed	Withdrawn / Not followed	CSR
Insert. – 1 year	6253	57	1116	99.1%
1 – 2 years	5080	5	1097	99.0%
2 – 3 years	3978	2	419	98.9%
3 – 4 years	3557	1	534	98.9%
4 – 5 years	3022	6	404	98.7%
5 – 6 years	2612	6	748	98.5%
6 – 7 years	1858	1	163	98.4%
7 – 8 years	1694	2	85	98.3%
8 – 9 years	1607	4	96	98.1%
9 – 10 years	1507	1	100	98.0%
10 – 11 years	1406	1	953	97.9%
11 years	452	–	–	–

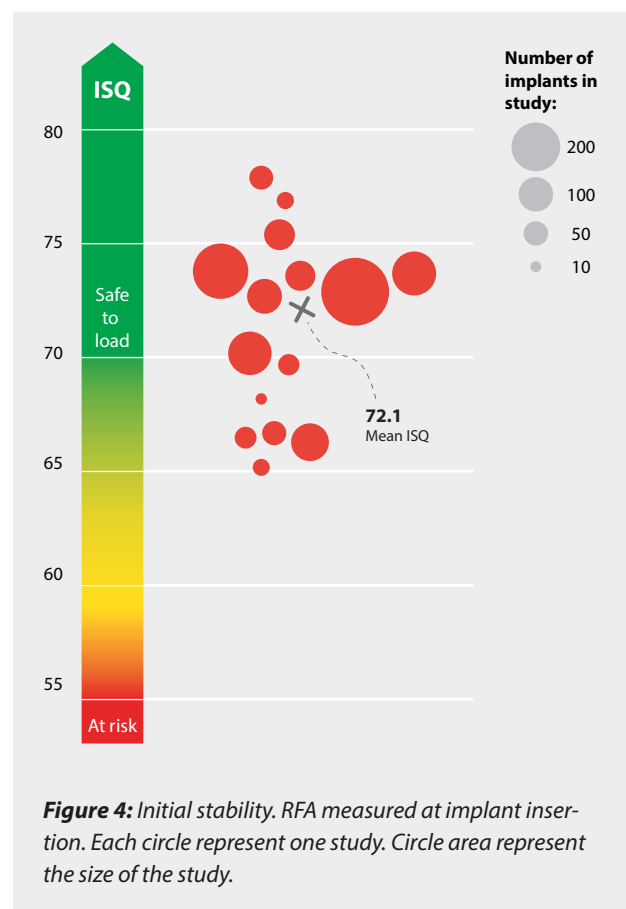
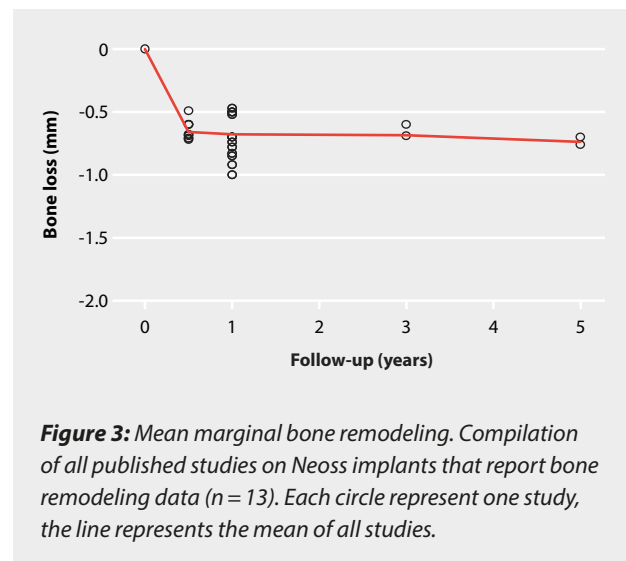
**Table 2:** Life table

#### Implant survival

The overall CSR for all ProActive implants was 99.1% after 1 year, 98.7% after 5 years, and 98.0% after 10 years (Table 2). The CSR for ProActive Straight implants was 99.3% after 1 year, 98.9% after 5 years, and 98.2% after 10 years. The CSR for ProActive Tapered implants was 98.4% after 1 year and 98.4% after 5 years. The CSR for ProActive Edge implants was 100% after 1 year (Figure 2).

#### Bone remodeling

The weighted mean bone loss in all studies was 0.66 mm after 1 year, and 0.74 mm after 5 years (Figure 3). None of the identified studies reported mean bone loss larger than 1.0 mm at any timepoint.



#### Implant stability

The weighted mean ISQ at time of implant insertion in all studies was 72.1 (range 65.2–77.9). The mean ISQ at implant insertion of each included study is shown in Figure 4.

In the studies that measured ISQ also after insertion, the mean weighted ISQ showed a steady increase over time: 70.8 at insertion, 71.7 at abutment connection, 71.8 after 6 months, and 74.3 after one year.<sup>2,3,6,7,8,17,22,24,25</sup>

Parameter	Groups	Study	Follow-up	CSR
Indication	Full arch	Sennerby 2016 Coli 2019 Acham 2017 <sup>1</sup>	1–6 years 2–5 years 3 years	96.5% 97.3% 100%
	Partial bridge	Andreatta 2020 <sup>3</sup> Zumstein 2019 <sup>23</sup> Schütz 2020 <sup>15</sup>	1 year 5 years 5 years	100% 98.9% 100%
	Single crown	Schütz 2020 <sup>15</sup>	5 years	100%
Implant type	Straight	Hassfurth 2021 <sup>9</sup> Zumstein 2019 <sup>23</sup> Maddalone 2020 <sup>11</sup>	10 years 5 years 1–7 years	98.4% 98.7% 100%
	Tapered	Schütz 2020 <sup>15</sup> Zwaan 2016 <sup>25</sup> Andreatta 2020 <sup>3</sup>	5 years 1 year 1 year	100% 96.9% 100%
	Edge	Turra 2020 <sup>19</sup>	1 year	100%
	Short 7 mm	Rosen 2018 <sup>14</sup>	1–7 years	94.8%
	Narrow 3.25	Vanden Bogaerde 2019 <sup>21</sup>	18 months	98.0%
	Sinus 6.5	van Thoor 2019 <sup>20</sup>	1–5 years	99.0%
Surgical protocol	One-stage	van Thoor 2019 <sup>20</sup> Sennerby 2016 <sup>16</sup>	1–5 years 1–6 years	99.0% 96.5%
	Two-stage	Hassfurth 2020 <sup>10</sup> Coppe 2019 <sup>5</sup> Di Lallo 2014 <sup>7</sup>	1–9 years 5 years 1 year	97.7% 98.0% 100%
Loading protocol	Immediate loading	Coli 2019 <sup>4</sup> Vanden Bogaerde 2019 <sup>21</sup> Andreatta 2020 <sup>3</sup>	2–5 years 18 months 1 year	97.3% 98.0% 100%
	Early loading	Sennerby 2016 <sup>16</sup> Shaheen 2020 <sup>17</sup> Turra 2020 <sup>19</sup>	1–6 years 1 year 1 year	96.5% 97.5% 100%
	Delayed loading	Coppe 2019 <sup>5</sup> Rosen 2019 <sup>13</sup> Di Lallo 2014 <sup>7</sup>	5 years 1–9 years 1 year	98.0% 96.5% 100%
Treatment concept	Sinus lift	van Thoor 2019 <sup>20</sup> Di Lallo 2014 <sup>7</sup>	1–5 years 1 year	99.0% 100%
	Bone augmentation	Hassfurth 2020 <sup>10</sup> Zumstein 2019 <sup>23</sup> Schütz 2020 <sup>15</sup>	1–9 years 5 years 5 years	97.7% 98.9% 100%
	Immediate placement	Sennerby 2016 <sup>16</sup> Coli 2019 <sup>4</sup> Vanden Bogaerde 2019 <sup>21</sup>	1–6 years 2–5 years 18 months	96.5% 97.3% 98.0%
	Tilted implants	Maddalone 2020 <sup>11</sup>	1–7 years	100%
	Overdenture	Acham 2017 <sup>1</sup> Elsyad 2021 <sup>8</sup> Shawky 2020 <sup>18</sup>	3 years 1 year 1 year	100% 97.5% 100%
Populations	Geriatric patients	Rosen 2019 <sup>13</sup>	1–9 years	96.5%

**Table 3:** Selected publications for different subgroups.

## DISCUSSION

### Implant survival

The combined CSR for Neoss ProActive implants in the identified literature was 98.7% after 5 years and 98.0% after 10 years. The identified studies contain normal day-to-day

use as well as more demanding treatments such as guided bone regeneration (GBR), immediate loading after total tooth extraction, and sinus lift procedures. The diversity of included studies therefore reflects the clinical reality of implant use (Table 3). The CSR of Neoss ProActive implants

(98.7% after 5 years and 98.0% after 10 years) compares very well with systematic long-term data which showed 97.3% CSR after 5 years and 94.6% CSR after 10 years.<sup>26,27</sup>

#### *Bone remodeling*

The weighted mean bone loss in all studies was 0.66 mm after 1 year, and 0.74 mm after 5 years. This implies very stable bone levels after minimal bone remodeling during the first year (Figure 3).

The data indicate less bone loss for the Neoss implant system than what is shown in systematic long-term reviews of multiple implant systems. Doorenwaard et al reported a mean bone loss of 1.01 mm after 5 years, and Moraschini et al reported a mean bone loss of 1.3 mm after 10 years.<sup>26,27</sup>

Norton et al made a meta-analysis of bone remodeling for three major implant brands, reporting the following bone loss after 5 years: 0.35 mm for Astra Tech OsseoSpeed, 0.74 mm for Straumann SLA/SLActive, and 1.19 mm for Nobel Biocare TiUnite. The ProActive data is comparable to the Straumann data in this study. However, one detail to note is that none of the ProActive studies reported a mean less than 1.0 mm at any timepoint, this is unmatched by any of the three brands in the Norton et al review.<sup>28</sup>

It has little clinical implication if the bone level around an implant is 0.3 mm or 0.9 mm. However, the mean value is interesting because it indicates if there are a high percentage of cases that have lost a lot of bone. High percentage of cases with bone loss more than 2 or 3 mm will result in a higher mean bone loss value and higher standard deviations.

In the studies that report frequency data on bone loss on Neoss implants, 3.5% (16 of 456) had lost more than 2 mm and 0% (0 of 407) had lost more than 3 mm after 1 year. After 5 years, 4.9% (10 of 206 implant) had lost more than 2 mm and 1.5% (3 of 206) more than 3 mm.<sup>3,5,21,23,25</sup>

Derks et al studied the prevalence of peri-implantitis in a Swedish population. From the national implant data register they randomly selected 900 patients that had been treated with implant 9 years earlier and invited them to a free-of-cost examination. Implants were Straumann (32.6%), Nobel Biocare (39.4%), Astratech (18.4%) or other brands (9.4%). They found that 9.9% (157 of 1578) of all implants had lost more than 2 mm bone from baseline to 9 years and that 4.9% (78 of 1578) had lost more than 3 mm.<sup>29</sup>

Doornwaard et al reported that 18% of implants lost more than 2 mm bone, and 5 % lost more than 3 mm.<sup>26</sup>

Compared to Derks et al, the percentage of Neoss implants with more than 2 mm bone loss is halved (4.9% vs. 9.9%), and even lower compared to Doornwaard et al. This indicates that Neoss implants have a lower percentage

of high bone loss cases than the main competitor implants. Since peri-implant bone loss is one of the prerequisites for peri-implantitis, low incidence of bone loss means low incidence of peri-implantitis.

One can argue that the Derks data is over a longer follow up (9 years vs. 5 years), but the bone levels are usually relatively stable after the first year. It should also be noted that the Derks data might underestimate the bone loss in their study since they accepted radiographs as late as 2 years after surgery as baseline radiographs and therefore any bone loss that occurred before the baseline radiograph is not taken into account.

#### *Implant stability*

The state of the art knowledge defines ISQ >70 as high implant stability. This is a level that enables immediate and early loading of single tooth reconstructions.<sup>30</sup> The weighted mean ISQ in all studies was 72.1 (Figure 3). It can therefore be concluded that high initial implant stability is consistently achieved with the Neoss implant system, and that the primary stability is maintained or even increased during the first year after implant placement.

## CONCLUSION

This systematic review of the published literature on Neoss ProActive implants shows high implant survival (CSR 98.0% after 10 years), minimal bone resorption (average 0.74 mm after 5 years), and excellent primary and secondary stability in all types of bone.

## REFERENCES

1. Acham S, Rugani P, Truschnegg A, Wildburger A, Wegscheider WA, Jakse N. Immediate loading of four interforaminal implants supporting a locator-retained mandibular overdenture in the elderly. Results of a 3-year randomized, controlled, prospective clinical study. *Clin Implant Dent Relat Res*. 2017;19:895-900
2. Ali S, El Talawy D. Locator versus stress free implant bar attachments for two-implants immediately loaded by mandibular overdentures. A one year randomized study. *Egypt Dent J*. 2021;67:1345-1355.
3. Andreatta L, Bjursten Brailsford M, Zwaan J. A Simplified Prosthetic Implant Loading Protocol: 1-Year Clinical Follow-Up Study. *Int J Dent*. 2020;8832500.
4. Coli P, Sennerby L. Extraction of Remaining Teeth and Same Day Loading of Neoss ProActive Dental Implants with a Full-arch Fixed Provisional Bridge. A Survival Analysis. *J Dent Maxillofacial Res*. 2019;2:1-6.
5. Coppe M, Degasperis W, Andersson P, Verrocchi D, Sennerby L. 5-year Results of Neoss Dental Implants Restored at Implant-Level. A Retrospective Follow-Up Study. *J Dent Maxillofacial Res*. 2019;2:1-5.
6. Degasperis W, Andersson P, Verrocchi D, Sennerby L. One-year clinical and radiographic results with a novel hydrophilic titanium dental implant. *Clin Implant Dent Relat Res*. 2014;16:511-519

7. Di Lallo S, Ricci L, Orecchioni S, Piattelli A, Iezzi G, Perrotti V. Resonance frequency analysis assessment of implants placed with a simultaneous or a delayed approach in grafted and nongrafted sinus sites: a 12-month clinical study. *Clin Implant Dent Relat Res.* 2014;16:394-400
8. Elsyad MA, Alsabri MA, Elgamel M, Al-Tonbary GY. Resilient Stud Versus Bar Attachments for Immediately Loaded Implants Supporting Mandibular Overdentures: 1-year Randomized Controlled Clinical Trial. *Int J Oral Maxillofac Implants.* 2021;36:346-354
9. Hassfurth N, Hassfurth N. Long term clinical performance of superhydrophilic dental implants with more than 10 years follow-up. *Clin Oral Implants Res.* 2021;32(S22):156-157
10. Hassfurth N, Hassfurth N, Pons-Kühnemann J, Howaldt H, Schaaf H. GBR using non-resorbable membranes and simultaneous implant placement. A comparative retrospective study. *Clin Oral Implants Res.* 2020;31(S20):244
11. Maddaloni M, Mirabelli L, Breschigliaro S, Baldoni M. Radiographic evaluation of the bone remodeling on tilted osseointegrated implants: Follow-up at 1 year. *J Contemp Dent Pract.* 2020;21:464
12. Maryod WH, Salam EAA, Alkaranfily GA. Gold alloy metal clip versus nylon plastic clips of stress-free implant (SFI) bar used for immediately loaded 4-implant assisted mandibular overdentures. One-year randomized trial evaluating marginal bone loss and patient satisfaction. *Egypt Dent J.* 2022;68:817-830
13. Rosen AS, Rosen PS, Froum SJ, Sahlin H. A 1–9 year retrospective follow-up of dental implant treatment success in patients 70 years and older. *ISPRD Congress.* 2019:Poster 4
14. Rosen PS, Sahlin H, Seemann R, Rosen AS. A 1–7 year retrospective follow-up on consecutively placed 7-mm-long dental implants with an electrowetted surface. *Int J Implant Dent.* 2018;4:24
15. Schütz S, Zumstein T, Sahlin H, Sennerby S. A five-year retrospective follow-up study of tapered hydrophilic implants placed with or without GBR procedures. *Clin Oral Implants Res.* 2020;31(S20):263
16. Sennerby L, Coppe M, Andersson P, Verrocchi D. A 5-year clinical and radiographic follow-up of hydrophilic implants restored at implant level. *Clin Oral Implants Res.* 2016;27(S13):342
17. Shaheen NH. Clinical and radiographic outcomes of stress-free implant (SFI) bars and milled bars for early loaded implant supporting mandibular overdentures. A one-year randomized trial. *Egypt Dent J.* 2020;66:1699-1710
18. Shawky AF. Stress free versus hader bars for immediately loaded two-implant retained mandibular overdentures. A one-year randomized trial evaluating marginal bone loss and patient satisfaction. *Egypt Dent J.* 2020;66:1327-1339.
19. Turra M, Andersson P, Verrocchi D, Sennerby L. A retrospective case series report on a novel aggressively threaded and tapered implant. *Clin Oral Implants Res.* 2020;31(S20):257
20. van Thoor W. The van Thoor technique. A one-visit sinus lift approach using a 6.5 mm wide implant. *ISPRD Congress.* 2019: Poster 37
21. Vanden Bogaerde L, Guida A, Moretto D, Sicuro S, Sala D, Sennerby L. Immediate Function of 3.25 mm Diameter Implants in Aesthetic Regions. An 18-month Clinical, Radiographic and Resonance Frequency Analysis (RFA) Study. *J Dent Maxillofac Res.* 2019;2:1-6
22. Vanden Bogaerde L, Sennerby L. A Randomized Case-Series Study Comparing the Stability of Implant with Two Different Surfaces Placed in Fresh Extraction Sockets and Immediately Loaded. *Int J Dent.* 2016:8424931
23. Zumstein T, Schutz S, Sahlin H, Sennerby L. Factors influencing marginal bone loss at a hydrophilic implant design placed with or without GBR procedures: A 5-year retrospective study. *Clin Implant Dent Relat Res.* 2019;21:817-826
24. Zumstein T, Sennerby L. A 1-Year Clinical and Radiographic Study on Hydrophilic Dental Implants Placed with and without Bone Augmentation Procedures. *Clin Implant Dent Relat Res.* 2016;18:498-506
25. Zwaan J, Vanden Bogaerde L, Sahlin H, Sennerby L. A One-year Follow-up Study of a Tapered Hydrophilic Implant Design Using Various Placement Protocols in the Maxilla. *Open Dent J.* 2016;10:680-691
26. Doornewaard R, Christiaens V, De Bruyn H, Jacobsson M, Cosyn J, Vervaeke S, Jacquet W. Long-Term Effect of Surface Roughness and Patients' Factors on Crestal Bone Loss at Dental Implants. A Systematic Review and Meta-Analysis. *Clin Implant Dent Relat Res.* 2017;19:372-399
27. Moraschini V, Poubel LA, Ferreira VF, Barboza Edos S. Evaluation of survival and success rates of dental implants reported in longitudinal studies with a follow-up period of at least 10 years: a systematic review. *Int J Oral Maxillofac Surg.* 2015;44:377-388
28. Norton MR, Åström M. The Influence of Implant Surface on Maintenance of Marginal Bone Levels for Three Premium Implant Brands: A Systematic Review and Meta-analysis. *Int J Oral Maxillofac Implants.* 2020;35:1099-1111
29. Derks J, Schaller D, Hakansson J, Wennstrom JL, Tomasi C, Berglundh T. Effectiveness of Implant Therapy Analyzed in a Swedish Population: Prevalence of Peri-implantitis. *J Dent Res.* 2016;95:43-49
30. Sennerby L. Resonance frequency analysis for implant stability measurements. A review. *Integration Diagnostics Update.* 2015;1:1-11

# The Neoss ProActive Edge implant. Preliminary clinical experiences and results

Matteo Turra<sup>1,2</sup>, Peter Andersson<sup>1,2</sup>, Damiano Verrocchi<sup>2</sup>, Lars Sennerby<sup>1</sup>

<sup>1</sup> Clinica Feltre, Feltre, Italy

<sup>2</sup> Private practice, Fiera di Primiero, Italy

*This retrospective chart study reports on the preliminary experiences with the clinical use of the novel Neoss Edge implant with regard to surgical handling, primary stability, and implant survival. Implant placement was found to be easy and gave a sensation of firm stability as also confirmed with ISQ measurements. One of 56 implants was lost and there were no indications of adverse marginal bone loss.*


## INTRODUCTION

Dental implant procedures should be safe, swift, and predictable to give patients the best possible treatment when replacing missing teeth. From a surgical point of view, it is desirable to use simple drilling protocols and an implant design that can reach good primary stability and integrate in all bone densities. A novel implant with features such as marked tapering, high thread pitch and wide and sharp threads has recently been developed.<sup>1</sup> This implant design, the Neoss Edge implant, is intended to speed up and simplify the surgical placement as only one or two drills are needed according to the manufacturer. The Neoss Edge implant was found to be effective in an in vitro study and showed comparable or higher primary stability than two commercially available implants with similar geometry as assessed by insertion torque (IT), Implant Stability Quotient (ISQ) and displacement measurements.<sup>2</sup> A recent clinical case series study reported that 13 of 25 Edge implants could be placed after the use of one spiral drill only.<sup>1</sup> Moreover, the implants reached high stability also in maxillary bone, where most implants had been used.

The aim of the study was to retrospectively evaluate the primary stability and clinical performance of 54 Neoss Edge implants in 36 consecutive patients after up to 3 years in function.

## MATERIALS & METHODS

This retrospective case series study comprised of consecutive routine patients missing one or several teeth and previously treated with a novel dental implant (ProActive Edge, Neoss AB, Gothenburg, Sweden) (Figure 1) using a one-stage protocol and loaded for at least one year. Data related to patient, type of treatment, implants, bone conditions, and outcomes at annual check-ups were extracted from a simple computerized system (MS Excel, Microsoft, Redmond, USA) used to keep track on consecutive implant treatments in the clinic. The study followed the World Medical Association Declaration of Helsinki and the directives given by the local ethical committee at the Feltre Hospital, Feltre, Italy.



A total of 36 patients (28 female, 8 male) treated with 56 implants and with a mean follow-up time of  $2.7 \pm 0.7$  years were eligible for the study (Table 1). Nine implants had been placed in the mandible and 47 in the maxilla as support for 37 prosthetic devices: 16 single tooth replacements, 19 partial bridges, one full bridge and one overdenture (Table 2 and 3). The implants had been inserted according to a protocol using a 2.2 mm straight drill and tapered spiral drills (3.0 – 4.4 mm) and, if needed, a countersink bur. Insertion torque (IT)/time curves had been registered during placement with an Elcomed drilling unit (W&H Austria GmbH, Bürmoos, Austria). Resonance frequency analysis (RFA) measurements had been taken after implant placement using a PenguinRFA instrument (IDSAB, Gothenburg, Sweden). Impressions were made after surgery or after 6 to 12 weeks of healing for loading with a permanent prosthetic device.

Any notations in the patient charts of biologic (failure, marginal bone resorption, infection, pain etc) and/or technical (fracture, chipping) complications at follow-up appointments and annual check-ups were registered.

## RESULTS

### Clinical observations

Insertion of the Edge implant was found to be easy and gave a sensation of high stability irrespective of bone density. Most of the 3.5 mm implants could be placed after the use of one 2.2 mm spiral drill only (Figure 2). The remaining implants were placed after using two spiral drills (Figure 3).

Number of implants <i>(failed)</i>		Implant diameter				Total
		3.5 mm	4.0 mm	4.5 mm	5.0 mm	
Implant length	9 mm	1	6	5 <i>(1)</i>	–	12
	11 mm	10	10	2	3	25
	13 mm	8	8	3	–	19
	Total	19	24	10	3	56

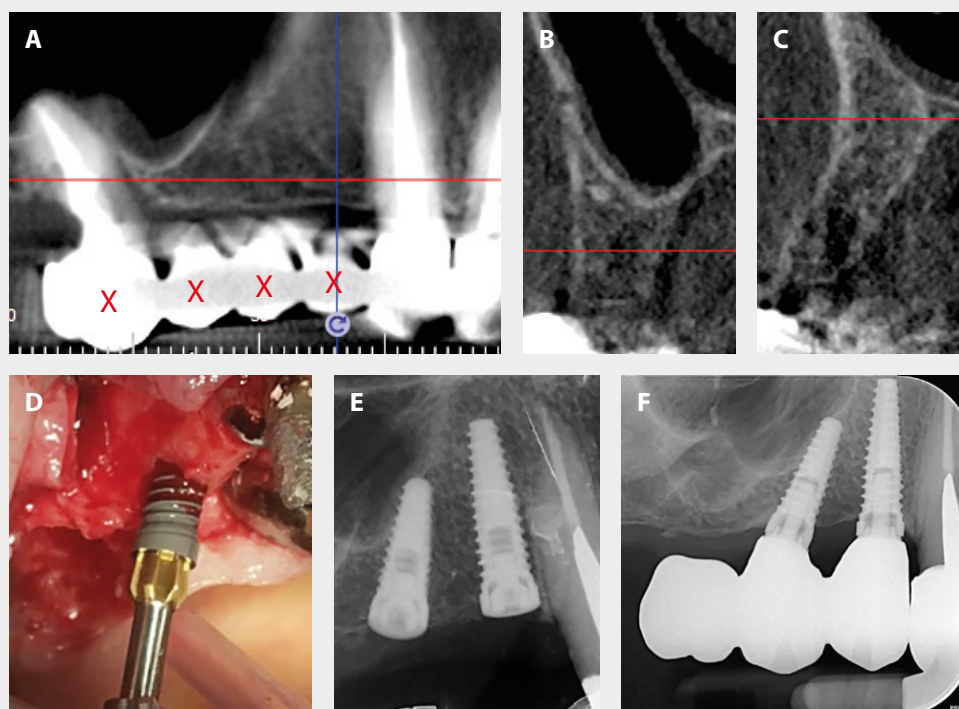
**Table 1:** Distribution of implants by implant length and diameter

Number of implants <i>(failed)</i>		Tooth position			Total
		Front	Premolar	Molar	
Jaw	Maxilla	6	24	17 (1)	47
	Mandible	2	4	3	9
	Total	8	28	20	56

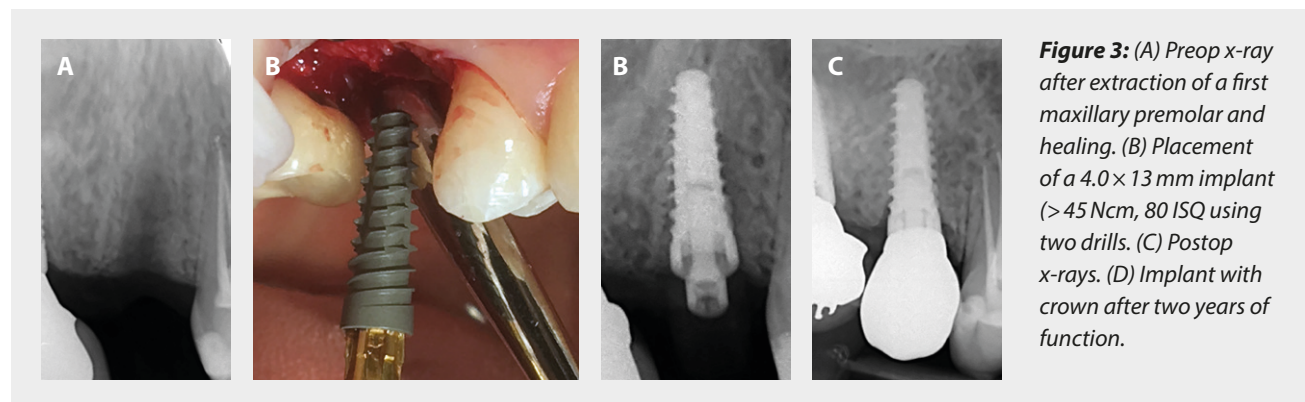
**Table 2:** Distribution of implants by jaw and tooth position

Number of constructions (failed)		Type of construction			Total
		Single tooth	Partial bridge	Full bridge / OD	
Jaw	Maxilla	12 (1)	17	1	30
	Mandible	4	2	1	7
	Total	16	19	2	37

**Table 3:** Distribution of prosthetic constructions by jaw and type of construction



**Figure 2:** (A) Pre-operative x-rays showing failing bridge spanning from canine to second molar. Treatment plan: extraction of molar, keeping canine and placement of two implants. (B) and (C) CBCT showing bone volumes in planned implant positions. (D) Placement of posterior implant. Note hydrophilicity. (E) Postop x-ray after placement of one 3.5 × 11 mm (13 Ncm, 76 ISQ) and one 3.5 × 13 mm (23 Ncm, 77 ISQ) implant with the use of one drill only. (F) Showing the final bridge after one year of loading.



No countersink bur was used for 15 implants. When using a second tapered drill, almost half the length of the implant could be placed into the osteotomy, which together with the high thread pitch resulted in a swift placement (Figure 4). In most cases the implant could be inserted to the desired position in one go, i.e. with the collar flush with or slightly below the crest. Only a few implants needed to be finally seated with the manual wrench.

Time interval	Implants	Failed	Withdrawn / Not followed	CSR
Insert. – 1 year	56	1	0	98.2%
1 – 2 years	55	0	14	98.2%
2 – 3 years	41	0	30	98.2%
3 years	11	–	–	–

**Table 4:** Life table

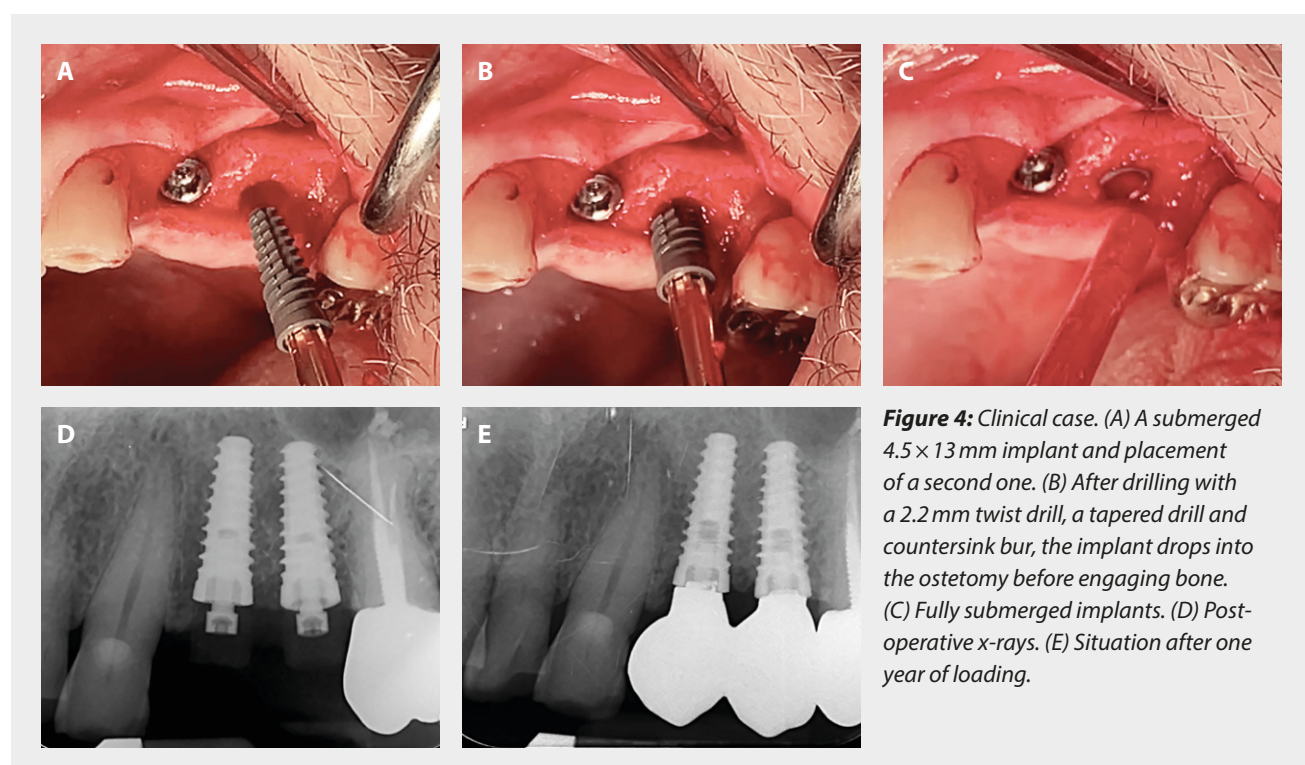
One implant was lost during the one-year of follow-up giving a survival rate of 98.3% (Table 4). The implant (4.5 × 9 mm, first maxillary molar position) failed due to infection six weeks after placement.

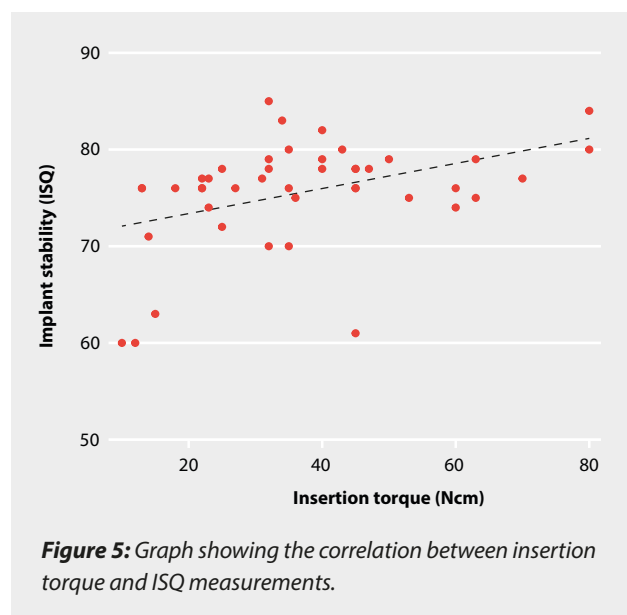
There were no notations of rapid marginal bone loss and infections around any implant.

#### Implant stability

All implants achieved firm primary stability as assessed with IT ( $37.2 \pm 17.7$  Ncm, range 10–80 Ncm) and RFA ( $75.5 \pm 5.2$  ISQ, range 60–85 ISQ) measurements.

There was a weak correlation between IT/bone density and RFA values as also implants with low IT/low density generally showed high ISQ values (Figure 5).



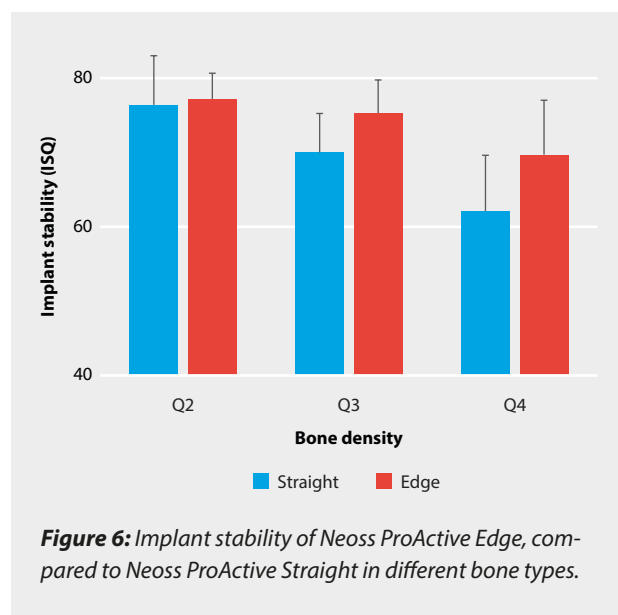


## DISCUSSION

The present case series report showed that the novel Neoss Edge implant and simplified drilling protocol resulted in firm primary implant stability and good clinical outcomes after up to three years of loading. One implant (1.7%) was lost due to infection during healing. Although no marginal bone level measurements were included in the study, no cases with extensive marginal bone loss and/or infection were experienced. In a previous report on the first fifteen patients of the same group, we reported a mean marginal bone loss of  $0.5 \pm 0.6$  mm after one year in function,<sup>1</sup> which is in line with studies on the other Neoss designs.<sup>5</sup>

A subjective feeling of high stability was obvious when placing the Edge implant, which was also confirmed by the RFA measurements. Interestingly, also implants with low IT and placed in soft bone generally showed firm stability. This is in line with the findings in vitro where the Edge implant showed high ISQ and low displacement values despite low insertion torque during the most challenging experimental conditions.<sup>2</sup> It was speculated that the wide collar of the implant was important as it enabled further clamping of the implant during insertion. A brief numerical comparison the present data with that from two previous clinical studies on Neoss Straight implants from our group,<sup>3,4</sup> indicated firmer stability for the Edge implants in these situations (Figure 6). However, this needs to be statistically confirmed in comparative studies.

The present authors are following a primary stability-based loading protocol (Andersson et al) where implants showing  $\geq 70$  heal for six weeks, 65–70 ISQ for 8 weeks and if  $\leq 65$  for 12 weeks. In addition, it is our experience that immediate/early loading can be successfully applied if



$\geq 70$  ISQ. In the present study, all but three implants showed such a high stability and may have been suitable for rapid loading. However, further studies are needed, since all implants in the present study was restored after healing.

It is concluded that surgical placement of the novel Neoss Edge implant was found to be easy and gave a sensation of high stability irrespective of bone density as also confirmed with IT and ISQ measurements. One implant was lost early after surgery and there were no indications of adverse marginal bone loss.

## REFERENCES

1. Turra M, Andersson P, Verrocchi D, Sennerby L. A retrospective case series report on a novel aggressively threaded and tapered implant. *Clin Oral Implants Res.* 2020;31(S20):257
2. Turra M, Petersson A, Sennerby L. Primary stability of three different aggressively threaded and tapered implants in low-density polyurethane. *Clin Oral Implants Res.* 2020;31(S20):60-61
3. Coppe M, Degasperis W, Andersson P, Verrocchi D, Sennerby L. 5-year results of Neoss dental implants restored at implant-Level. A retrospective follow-up study. *J Dent Maxillofac Res.* 2019;2:1-5
4. Sennerby L, Andersson P, Pagliani L, Giani C, Moretti G, Molinari M, Motroni A. Evaluation of a novel cone beam computed tomography scanner for bone density examinations in preoperative 3D reconstructions and correlation with primary implant stability. *Clin Implant Dent Relat Res.* 2015;17:844-853
5. Sahlin H. Implant survival, bone remodeling and implant stability of Neoss implants: a systematic review of the literature. *Letters Implant Dent.* 2017;1:15-20

# Factors influencing 10-year survival of Neoss ProActive implants. A retrospective survey

Lars Sennerby<sup>1,2</sup>, Luca Pagliani<sup>3</sup>, Stefano Volpe<sup>4</sup>, Peter Andersson<sup>1,5</sup>,  
Damiano Verrocchi<sup>5</sup>

<sup>1</sup> Clinica Feltre, Feltre, Italy

<sup>2</sup> Private Practice, Gothenburg, Sweden

<sup>3</sup> Private Practice, Milano, Italy

<sup>4</sup> Private Practice, Rome, Italy

<sup>5</sup> Private Practice, Fiera di Primiero, Italy

*The present retrospective survey analyses factors of importance for implant failure in 466 patients treated with 1162 Neoss ProActive implants in five different centers. A cumulative survival rate of 98.2% was found after at least 10 years of function. Short implants in the posterior mandible as well as anterior maxillary implants placed in extraction sockets, with bone substitutes and immediately loaded and were more prone to failure. If regarding all late failures as caused by peri-implantitis the incidence was 0.9%.*

## INTRODUCTION

Many factors are involved when treating edentulous patients with dental implants, which may affect the long-term function and outcomes of the therapy. These factors relate to the patient, implant components, clinical techniques, involved clinicians' experience/skills and type of maintenance. Data from the scientific literature on which factors that are most important for implant failure are not conclusive and seems to differ between implant systems.<sup>1</sup> It is therefore important to evaluate the long-term response to each implant system.

Critical reports claim a high prevalence and incidence of peri-implantitis, and that severe marginal bone loss may lead to high numbers of subsequent implant losses.<sup>2</sup> It has also been suggested that implant systems with a rough surface morphology are more prone to peri-implantitis compared to machined implant surfaces.<sup>3</sup> However, implant surface seems to be of minimal importance for crestal bone loss.<sup>4</sup> The Neoss implant system has used two different surfaces, where the former Bimodal was smoother than the present hydrophilic ProActive surface. However,

clinical studies with up to five years of follow up have not demonstrated any differences regarding marginal bone loss.<sup>5</sup> Instead, the studies indicate higher survival rates for ProActive implants, especially in challenging cases, which is in line with clinical studies on other implant systems.<sup>6-8</sup>

The present retrospective study evaluated the survival rate of Neoss ProActive implants after at least 10 years of function. The study material was broken down in subgroups representing different factors and subjected to statistical analyses to find a possible impact on the survival rate.

## MATERIALS & METHODS

### Patients

Five implant centres were invited to provide with data from consecutive patient treatments with Neoss ProActive implants, which had been followed for at least ten years in function. All type of procedures were included. The anonymized data were extracted from the patient charts at each clinic and entered into a spread sheet for further analysis (MS Excel, Microsoft, Redmond, USA). Information about gender, age, bone conditions, type and number of implants,

		Implant diameter						Total
		3.25 mm	3.5 mm	4.0 mm	4.5 mm	5.0 mm	5.5 mm	
Implant length	7 mm	–	–	19	6	2	–	27
	9 mm	5	4 (1)	105	26 (4)	21 (2)	1	162 (7)
	11 mm	10	18	224 (2)	57 (2)	41	1	351 (4)
	13 mm	13 (1)	24 (1)	262 (4)	54 (1)	5	2	360 (7)
	15 mm	2	23 (1)	212 (2)	19	2	–	258 (3)
	17 mm	–	1	3	–	–	–	4
	Total	30 (1)	70 (3)	825 (8)	162 (7)	71 (2)	4	1162 (21)

**Table 1:** Number of implants per implant length and diameter. Number of failed implants within brackets.

		Tooth position			Total
		Anterior	Premolar	Molar	
Jaw	Maxilla	225 (9)	297 (3)	141	663 (12)
	Mandible	111 (1)	159 (1)	229 (7)	499 (9)
	Total	336 (10)	466 (4)	370 (7)	1162 (21)

**Table 2:** Number of implants in different tooth regions. Number of failed implants within brackets.

		Prosthetic construction				Total
		Full bridge	Overdenture	Partial bridge	Single crown	
Jaw	Maxilla	48 (4)	–	100 (4)	133 (4)	281 (10)
	Mandible	32 (1)	8	97 (4)	107 (4)	244 (9)
	Total	80 (5)	8	197 (8)	240 (8)	532 (19)

**Table 3:** Type and number of prosthetic constructions. Number of constructions with implant failure within brackets.

tooth position, implant stability, type of prosthesis, follow-up time, and possible implant loss were analysed. The primary parameter was implant failure. The study followed the World Medical Association Declaration of Helsinki and the directives given by the local ethical committee at the Feltre Hospital, Feltre, Italy.

#### Statistics

A Chi-Squared test was used for statistical comparison of proportions between subgroups of implants representing different factors. A statistically significant difference was considered if  $p \leq 0.05$ .

#### RESULTS

Data from 466 patients (243 females, 223 males, mean age  $58.6 \pm 13.7$  years) were available from the five centres for analysis. A total of 81 patients and 202 implants were registered as drop-outs due to death ( $n=43$ ) or they had moved ( $n=38$ ).

A total of 1162 Neoss ProActive Straight implants had been used to support 532 prosthetic constructions in both jaws (Tables 1 to 3).

A total of 21 implant failures (1.8%) were noted in 19 patients (4.1%). Eleven (0.9%) were early (occurring  $4.0 \pm 1.6$  months after surgery) and ten (0.9%) late failures (occurring  $7.1 \pm 2.9$  years after surgery). The eleven early failures were mainly seen at abutment connection surgery or after commencing immediate/early loading with a temporary fixed bridge. The ten late failures were in general due to ongoing marginal bone resorption. Five of the failures involved 9 mm implants in the posterior mandible.

Chi-Square tests indicated that implant failure was more common for short implants ( $\leq 9$  mm), in the anterior region and in molar positions in the mandible (Table 4). There were no significant differences between jaws, implant diameters, immediate/early or conventional loading, sinus lift or no sinus lift and for implants in extraction sockets or healed sites.

## DISCUSSION

The present retrospective survey of 466 patients and 1162 Neoss ProActive implants from five centres showed a survival rate of 98.2% after at least ten years in function, which corroborates with the results from other studies on various modern implant systems.<sup>9</sup> It should be pointed out that the patients were not actively examined after ten years, and that data were extracted from patient charts. Moreover, some 17% of the patients were drop-outs due to death or not regularly examined for other reasons, which means that the failure rate may be higher than reported. However, it is our experience that few patients drop-out because of dissatisfaction and will show up in case of problems.

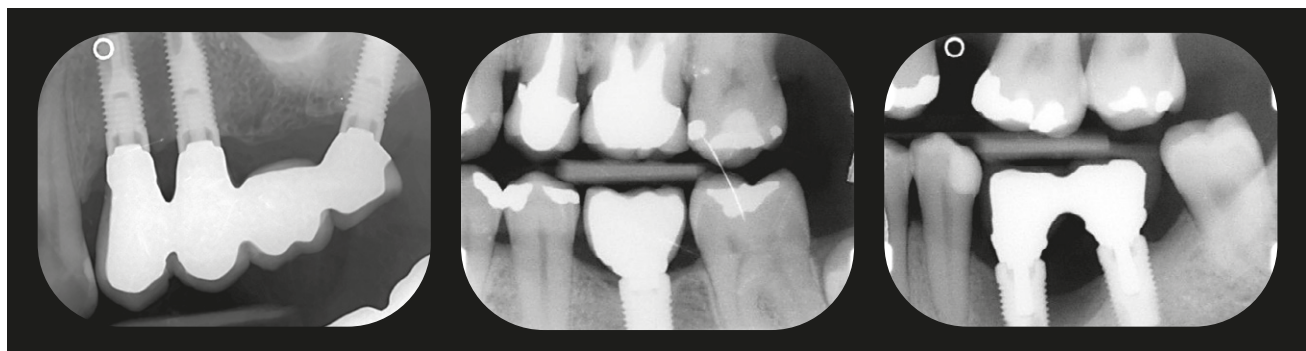A statistical analysis of the proportion between subgroups of implants showed that short and mandibular implants were less successful than the remaining implants. It was obvious that this was due to that five of the ten late failures were 9 mm implants in mandibular molar positions, which is a region subjected to high loads. Moreover, the maxillary anterior region showed a higher failure rate, mainly due to early loss of implants. The majority of these had been either immediately loaded, placed in an extraction socket or subjected to bone augmentation, which may have challenged the integration process. However, the survival rates ranging from 96.7 to 97.0% for the worst subgroups still represent excellent 10-year outcomes.

If regarding all late losses as peri-implantitis cases, the incidence was 0.9% after ten years. However, according to the patient charts, not all losses were associated with infection and suppuration. Our results are in line with other studies and show that peri-implantitis is not a determinant of success when using implant failure as endpoint.<sup>9</sup>

Parameter	Group	n	%	Significance
Overall	Total	21/1162	1.8	–
Timing of failure	Early	11/1162	0.9	NS
	Late	10/1162	0.9	
Jaw	Maxilla	12/633	1.8	NS
	Mandible	9/499	1.8	
Implant length	≤ 9 mm	7/189	3.7	p = 0.029
	> 9 mm	14/973	1.4	
Implant diameter	≤ 3.5 mm	4/100	4.0	NS
	> 3.5 mm	17/1062	1.6	
Loading protocol	Immediate/early	4/241	1.7	NS
	Conventional	17/921	1.8	
Sinus lift	Sinus lift	0/45	0	NS
	No sinus lift	21/1117	1.9	
Site	Extraction socket	1/23	4.3	NS
	Healed	20/1139	1.8	
Implant position	Anterior	10/336	3.0	p = 0.0032 (Ant. vs Post.) NS (other)
	Premolar	4/466	0.9	
	Molar	7/370	1.9	
	Anterior maxilla	9/225	4.0	NS
	Anterior mandible	1/111	0.9	
	Premolar maxilla	3/297	1.0	NS
	Premolar mandible	1/159	0.6	
	Molar maxilla	0/141	0	p = 0.038
	Molar mandible	7/229	3.0	

**Table 4:** Subgroup analysis of implant failures. Significance testing between groups using Chi-Squared test. NS = not statistically significant ( $p > 0.05$ ).

It is concluded that the use of Neoss ProActive implants on all indications result in high survival rates after ten years of function.



**Figure 1:** Radiograph after 10 years of function showing a 4-unit bridge in premolar and molar region.

**Figure 2:** Radiographs of a single molar construction after 10 years of function.

**Figure 3:** Radiograph of a failing construction after 10 years of function. Two 5.0×9 mm implants were placed to replace first and second molars. Note bone resorption between the implants and loss of the mesial implant.

## REFERENCES

1. Chrcanovic BR, Albrektsson T, Wennerberg A. Reasons for failures of oral implants. *J Oral Rehabil*. 2014;41:443-476
2. Lang NP, Berglundh T. Peri-implant diseases: where are we now? Consensus of the Seventh European Workshop on periodontology. *J Clin Periodontol* 2011;38:178–181
3. Garaicoa-Pazmino C, Lin GH, Alkandery A, Parra-Carrasquer C, Suárez-López Del Amo F. Influence of implant surface characteristics on the initiation, progression and treatment outcomes of peri-implantitis: A systematic review and meta-analysis based on animal model studies. *Int J Oral Implantol* 2021;14:367-382
4. Doornewaard R, Christiaens V, De Bruyn H, Jacobsson M, Cosyn J, Vervaeke S, Jacquet W. Long-Term Effect of Surface Roughness and Patients' Factors on Crestal Bone Loss at Dental Implants. A Systematic Review and Meta-Analysis. *Clin Implant Dent Relat Res*. 2017;19:372-399
5. Sahlin H. Implant survival, bone remodeling and implant stability of Neoss implants: a systematic review of the literature. *Letters Implant Dent* 2017;1;15-20
6. Zumstein T, Billström C, Sennerby L. A 4- to 5-year retrospective clinical and radiographic study of Neoss implants placed with or without GBR procedures. *Clin Implant Dent Relat Res*. 2012;14:480-90
7. Zumstein T, Schütz S, Sahlin H, Sennerby L. Factors influencing marginal bone loss at a hydrophilic implant design placed with or without GBR procedures: A 5-year retrospective study. *Clin Implant Dent Relat Res*. 2019;21:817-826
8. Jemt T. Implant Survival in the Edentulous Jaw: 30 Years of Experience. Part II: A Retro-Pro prospective Multivariate Regression Analysis Related to Treated Arch and Implant Surface Roughness. *Int J Prosthodont*. 2018;31:531-539
9. Albrektsson T, Buser D, Sennerby L. Crestal bone loss and oral implants. *Clin Implant Dent Relat Res* 2012;14:783–791

# Extraction of remaining teeth and same-day load of Neoss ProActive implants with a provisional full-arch fixed bridge

Pierluigi Coli<sup>1</sup>, Lars Sennerby<sup>2</sup>

<sup>1</sup> Edinburgh Dental Specialists, Edinburgh, UK

<sup>2</sup> Clinica Feltre, Feltre, Italy

*This retrospective analysis of 331 implants (Neoss ProActive Straight) in 61 patients placed in conjunction with tooth extraction and loaded the same day with a full-arch fixed bridge showed a survival rate of 98.5% after an average follow up of 4.8 years (range 2 – 7 years).*

## INTRODUCTION

Immediate loading of dental implants is an attractive treatment modality as the patient can be offered restored function and aesthetics the same day.<sup>1,2</sup> However, it is a logistic challenge to offer this to all suitable implant patients in a busy dental practice since it is a resource demanding procedure. Those who suffer from the functional and aesthetic consequences of a diseased remaining dentition represent one group of patients where immediate loading is justified and highly effective.<sup>3</sup> Furthermore, these patients may not have seen a dentist for a long time due to severe dental fear. Our experience is that these patients can be motivated to go through one surgical procedure including removal of remaining teeth and placement of implants followed by the manufacturing and loading of a provisional bridge the same day,<sup>4</sup> as also reported by other authors.<sup>5–7</sup> Systematic reviews have concluded that immediate/early loading is a straightforward approach in the mandible,<sup>8</sup> while treatment of the maxilla is less well documented,<sup>9–11</sup> particularly when implants are placed in extraction sockets.<sup>11</sup>

The aim of the present retrospective chart study was to analyze implant survival and complications in 61 consecutive patients treated with same day loading of 71 full-arch implant-supported temporary bridges in conjunction with tooth extractions.

## MATERIALS & METHODS

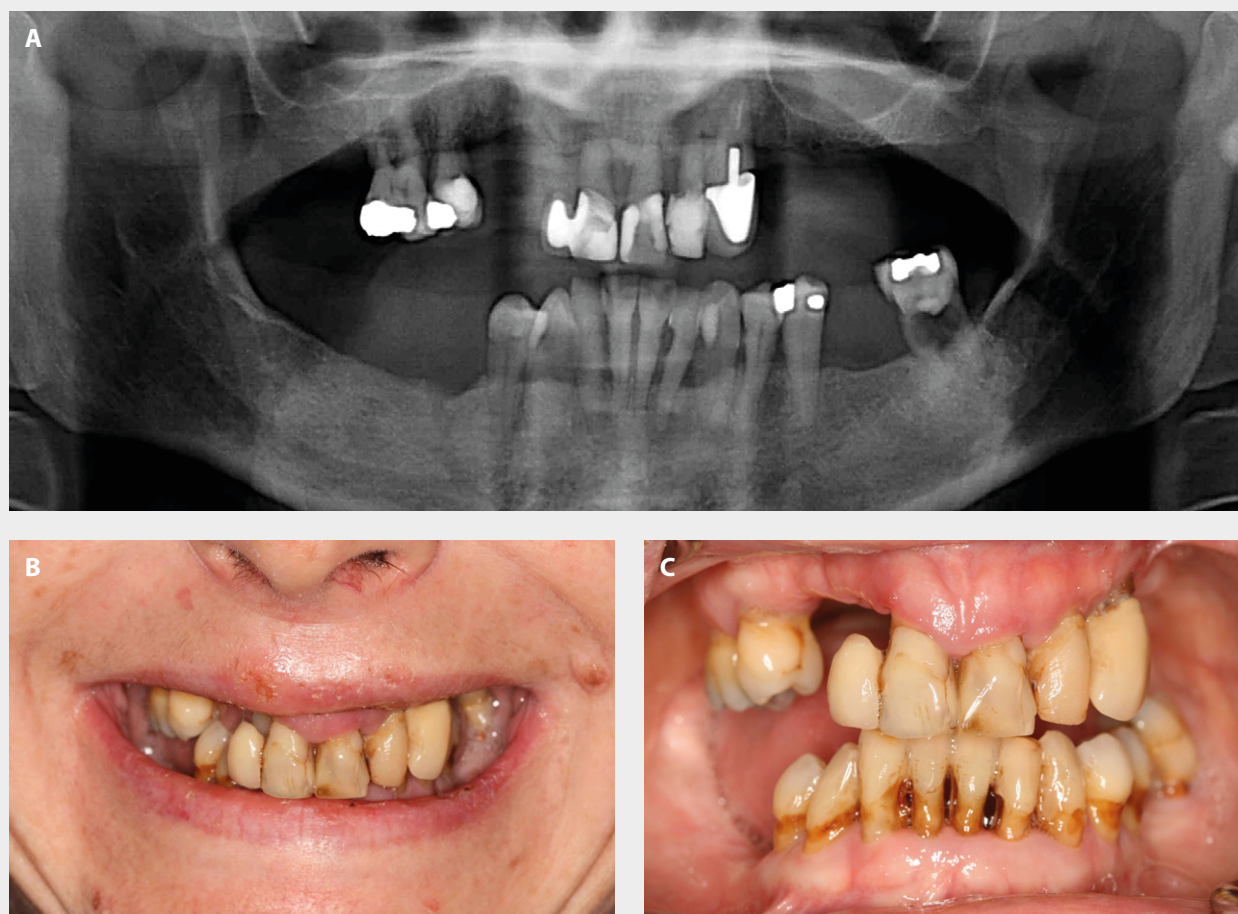### *Patients and data collection*

This retrospective chart study includes consecutive patients treated with an immediately loaded fixed full-arch bridge on Neoss implants (ProActive Straight, Neoss, Gothenburg, Sweden) in conjunction with extraction of remaining teeth in the maxilla and/or mandible at the Edinburgh Dental Specialist referral clinic, Edinburgh, Scotland and with at least two years of follow-up. The study was made in accordance with the World Medical Association Declaration of Helsinki.

### *Clinical procedures*

The treatment consisted of extraction of the remaining dentition and the immediate placement of four to six dental implants (Neoss ProActive Straight) in the maxilla and four to five in the mandible (Figure 1 to 3). The implants were placed both in healed and extracted sites to achieve a good distribution of the implants within the jaw. Screw-retained transmucosal abutments (Access abutment, Neoss) or Multi Unit Abutments, (Nobel Biocare UK Ltd, Uxbridge, UK) were placed on the implants.

A provisional acrylic bridge was fabricated in the in-house dental laboratory and fitted after a few hours from the surgical procedures using screw retention (Figure 2).



**Figure 1:** Presurgical examination of a 48 year old female patient at initial consultation for treatment of both jaws. (A) Orthopantomogram. (B) Extraoral appearance. (C) Intraoral view.

#### Final bridges

The fabrication of the definitive prostheses was initiated between three to six months from the implant placement, depending on the amount of soft and hard tissue recession expected after surgery, on the jaw (maxilla or mandible), on the time availability from the patient's and the prosthodontist's sides. The implants were restored with titanium/acrylic, metal/ceramic or zirconia prostheses (Figure 3).

Parameter	Group	n	%
Age	33 – 39	1	1.6
	40 – 49	5	8.2
	50 – 59	13	21.3
	60 – 69	23	37.7
	70 – 79	12	19.7
	80 – 89	7	11.5
Gender	Female	38	62.3
	Male	23	37.7

**Table 1:** Baseline patient parameters

Parameter	Group	n	%
Jaw	Maxilla	38	52.8
	Mandible	34	47.2
Number of teeth extracted per reconstruction	3	5	6.9
	4	4	5.6
	5	7	9.7
	6	10	13.9
	7	12	16.7
	8	6	8.3
	9	9	12.5
	10	10	13.9
	11	3	4.2
	12	3	4.2
	13	1	1.4
	No extractions	2	2.8
Number of implants per reconstruction	2	3	4.2
	3	2	2.8
	4	24	33.3
	5	38	52.8
Existing implants in bridge	Yes	8	11.1
	No	64	88.9
Abutment type	Access	30	41.7
	Multi-unit	42	58.3

**Table 2:** Baseline reconstruction parameters

Parameter	Group	n	%
Implant position	Anterior maxilla	109	32.9
	Posterior maxilla	76	23.0
	Anterior mandible	70	21.1
	Posterior mandible	76	23.0
Jaw	Maxilla	185	55.9
	Mandible	146	44.1
Implant length	9 mm	9	2.7
	11 mm	46	13.9
	13 mm	276	83.4
Implant diameter	3.5 mm	41	12.4
	4.0 mm	260	78.5
	4.5 mm	27	8.2
	5.0 mm	3	0.9
Type of abutment	Access	141	42.6
	Multi-unit	190	57.4

**Table 3:** Baseline patient parameters

Number of implants		Implant diameter				Total
		3.5 mm	4.0 mm	4.5 mm	5.0 mm	
Implant length	9 mm	–	3	4	2	9
	11 mm	8	32	5	1	46
	13 mm	33	225	18	–	276
	Total	41	260	27	3	331

**Table 4:** Distribution of implants by implant length and diameter

#### Follow-ups

A follow-up appointment was carried out after 3–4 weeks and patients were thereafter scheduled for recalls once a year the first two years, thereafter at the fifth, seventh, 10th anniversary and every 2–3 years thereafter. At these appointments, assessments of the integrity of the prostheses and of the soft and hard peri-implant tissues conditions by clinical and radiographic examinations were carried out.

#### RESULTS

A total of 61 patients (38 female, 23 male, mean age  $64.6 \pm 11.7$  years) treated in 72 jaws (38 maxillae, 34 mandibles) were included in the study (Table 1).

Time interval	Implants	Failed	Withdrawn / Not followed	CSR
Insert. – 1 year	331	5	0	98.5%
1 – 2 years	326	0	0	98.5%
2 – 3 years	326	0	56	98.5%
3 – 4 years	270	0	75	98.5%
4 – 5 years	195	0	61	98.5%
5 – 6 years	134	0	37	98.5%
6 – 7 years	97	0	64	98.5%
7 – 8 years	33	0	33	98.5%
8 years	0	–	–	–

**Table 5:** Life table

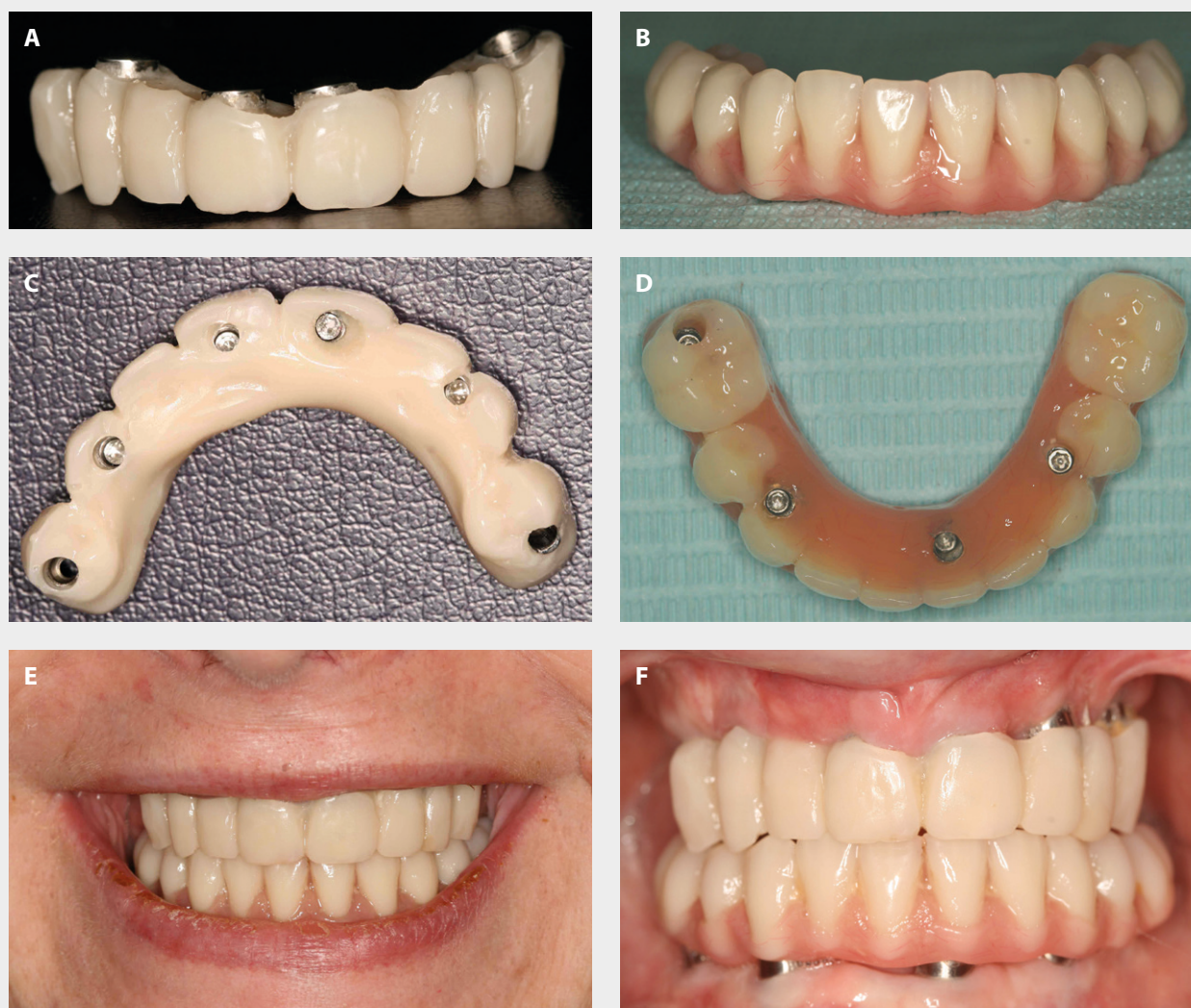
Eleven patients had been treated in both jaws at two different occasions. On average, seven teeth ( $6.9 \pm 2.8$ ) were extracted in each jaw (Table 2) and treated with 331 Neoss ProActive Straight implants, where 185 had been placed in the maxilla (38 jaws) and 146 in the mandible (34 jaws) (Tables 2, 3 and 4). In five cases, previously placed implants were included in the bridge.

A total of five implants failed in four patients during the follow-up period giving a cumulative survival rate of 98.5% after a mean follow-up of  $4.8 \pm 1.6$  years (range 2–7 years) (Table 5). Three failures occurred in the maxilla (1.6%) in two patients because of fracture of the temporary bridge and two in the mandible (1.4%) in one patient due to infection (Table 6). These three patients had new implants placed and could maintain the repaired bridge ( $n=3$ ) or received a newly made temporary bridge including the newly placed implants ( $n=1$ ) during the additional healing period. No implant failures were observed after placement of the permanent fixed bridges.

Although not quantified in the present study, the peri-implant marginal bone levels were maintained throughout the observation period and no implant required removal or any additional treatment due to bone loss.

Pat. ID	Gender	Age	Position	Dimensions	No extr. teeth	No implants in bridge	Reason	Failure time
7	Female	68	Second premolar	4.0 × 13 mm	9	4	Infection	7 months
7	Female	68	Lateral incisor	4.0 × 13 mm	9	4	Infection	7 months
18	Female	40	Second premolar	4.0 × 13 mm	6	6	Fracture prov bridge	3 months
29	Female	63	Second premolar	4.0 × 13 mm	5	5	Fracture prov bridge	3 months
50	Female	75	First molar	5.0 × 9 mm	6	5	Fracture prov bridge	3 months

**Table 6:** Specification of failed implants



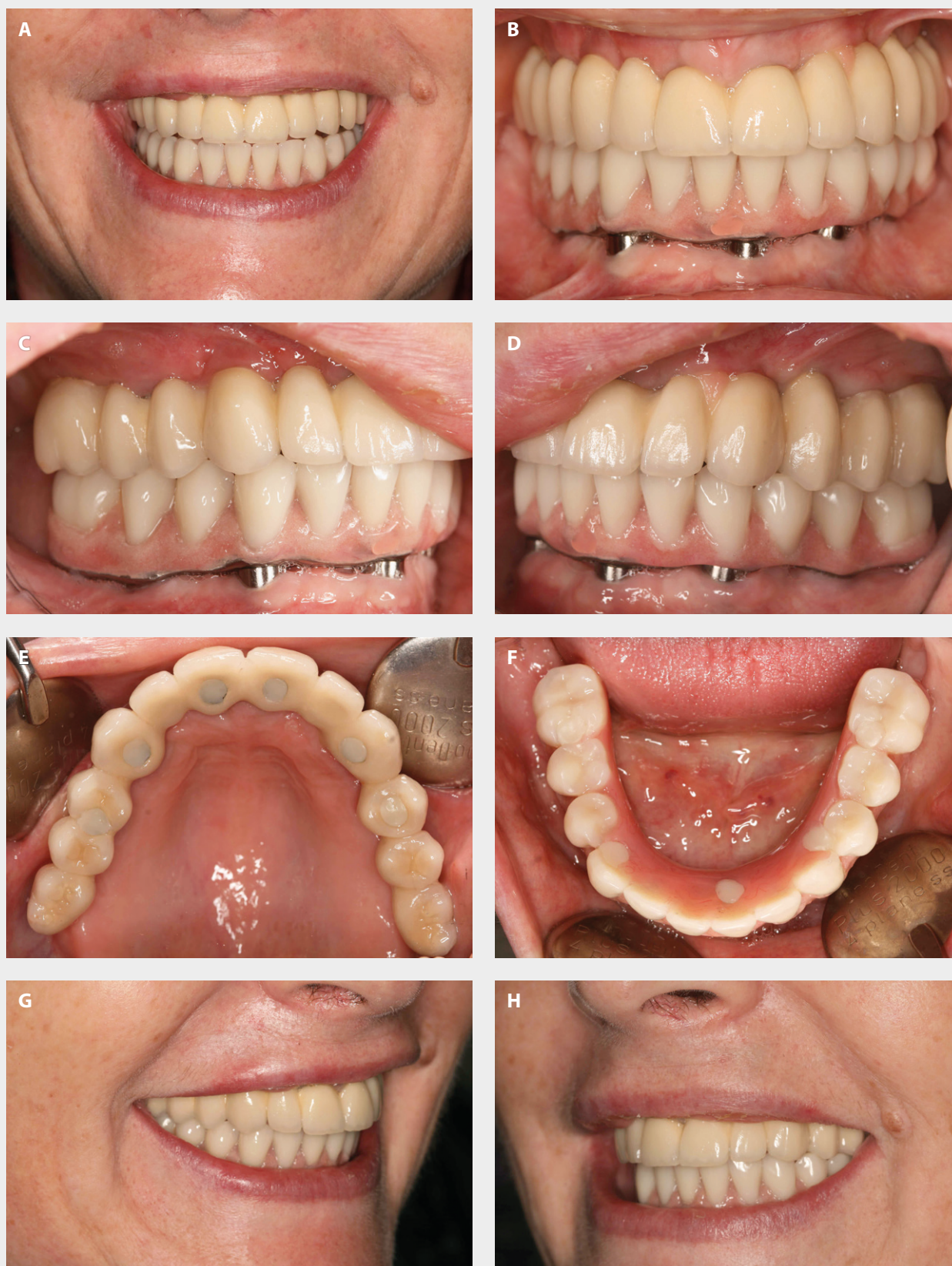**Figure 2:** (A–B) Provisional acrylic bridge for the upper and lower jaw. (C–D) Occlusal views of upper and lower bridge. (E–F) Extraoral and intraoral appearance with both provisional bridges fitted on the implants.

Few technical complications were noted. The provisional acrylic prostheses fractured during the healing time in seven patients. In two cases, the fractures of the provisional restorations led to overload and implant failure. During the follow-up period, four patients experienced the fracture of an acrylic tooth from the permanent restoration. In all cases, the prostheses were repaired in the laboratory within few hours and refitted the same day.

## DISCUSSION

The present retrospective study based on 61 patients and 72 bridges showed that immediate loading of fixed implant-supported provisional bridges in conjunction with extraction of remaining teeth is a highly effective and successful treatment modality as also shown by other authors.<sup>2</sup> Since maintenance of an implant-retained prosthesis was the primary objective of the treatment, the survival rate of the

restorations described in this study was 100% after 2 to 7 years of function with few minor prosthetic complications that could be amended within few hours. It is likely that the ProActive surface played an important role for the good outcomes. For instance, Andersson et al utilized the similar treatment and same implant design as in this study, but with two different surfaces and observed better results with the ProActive surface than for the Bimodal surface, 96.4% vs 89.7%.<sup>12</sup> Experimental and clinical studies have shown a strong bone tissue response to the ProActive surface in comparison with other implant surfaces as measured with removal torque tests and resonance frequency analysis (RFA) measurements.<sup>13,14</sup> In addition, other clinical studies have demonstrated higher stability and better clinical outcomes with ProActive than with Bimodal implants.<sup>15</sup> There were no notations of any problems with marginal bone loss or peri-implantitis in the present retrospective chart study.



**Figure 3:** Final bridges. (A) Extraoral view with final bridges fitted. (B) Intraoral frontal view, (C) Right and (D) left side. (E) Occlusal view of the upper and (F) lower bridges. (G–H) Oblique extraoral view of final bridges.

Many of the patients in this investigation had a history of poor functioning removable prostheses, constant discomfort and often pain due to failing dentition, low self-esteem, and limited social life. It was obvious that for many of the patients the one-day treatment approach had a dramatic effect as it clearly improved their life quality and self-esteem almost immediately.<sup>16</sup>

It is concluded that extraction of remaining dentition and same day loading of a provisional full-arch bridge on Neoss ProActive implants resulted in a high implant survival rate and few complications in both the mandible and maxilla after a follow-up of 2 to 7 years.

## REFERENCES

1. De Bruyn H, Raes S, Ostman PO, Cosyn J. Immediate loading in partially and completely edentulous jaws: a review of the literature with clinical guidelines. *Periodontol* 2000. 2014;66:153–187
2. Jiang X, Zhou W, Wu Y, Wang F. Clinical Outcomes of Immediate Implant Loading with Fixed Prostheses in Edentulous Maxillae: A Systematic Review. *Int J Oral Maxillofac Implants*. 2021;36:503–519
3. Emami E, de Souza RF, Kabawat M, Feine JS. The impact of edentulism on oral and general health. *Int J Dent*. 2013;498305
4. Coli P and Sennerby L. Extraction of Remaining Teeth and Same Day Loading of Neoss ProActive Dental Implants with a Full-arch Fixed Provisional Bridge. A Survival Analysis. *J Dent Maxillofac Res*. 2019;2:1–6
5. Balshi TJ, Wolfinger GJ. Immediate loading of Brånemark implants in edentulous mandibles: a preliminary report. *Implant Dent*. 1997;6:83–88
6. Wolfinger GJ, Balshi TJ, Rangert B. Immediate functional loading of Brånemark system implants in edentulous mandibles: clinical report of the results of developmental and simplified protocols. *Int J Oral Maxillofac Implants*. 2003;18:250–257
7. Olsson M, Urde G, Andersen JB, Sennerby L. Early loading of maxillary fixed cross-arch dental prostheses supported by six or eight oxidized titanium implants: results after 1 year of loading, case series. *Clin Implant Dent Relat Res*. 2003;5(S1):81–87
8. Papaspyridakos P, Mokti M, Chen CJ, Benic GI, Gallucci GO, et al. (2014) Implant and prosthodontic survival rates with implant fixed complete dental prostheses in the edentulous mandible after at least 5 years: a systematic review. *Clin Implant Dent Relat Res*. 2014;16:705–717
9. Attard NJ, Zarb GA. Immediate and early implant loading protocols: a literature review of clinical studies. *J Prosthet Dent*. 2005;94:242–258
10. Ostman PO. Immediate/early loading of dental implants. Clinical documentation and presentation of a treatment concept. *Periodontol* 2000. 2008;47:90–112
11. Strub JR, Jurdzik BA, Tuna T. Prognosis of immediately loaded implants and their restorations: a systematic literature review. *J Oral Rehab*. 2012;39:704–717
12. Andersson P, Degasperis W, Verrocchi D, Sennerby L. A Retrospective Study on Immediate Placement of Neoss Implants with Early Loading of Full-Arch Bridges. *Clin Implant Dent Relat Res*. 2015;17:646–657
13. Sennerby L, Gottlow J, Gottlow J (2017) Integration of Neoss ProActive implants in comparison with other brands of dental implants. *Letters Implant Dent*. 2017;1:7–20
14. Vanden Bogaerde L, Sennerby L. A Randomized Case-Series Study Comparing the Stability of Implant with Two Different Surfaces Placed in Fresh Extraction Sockets and Immediately Loaded. *Int J Dent*. 2016: 8424931
15. Zumstein T, Sahlin H. The evolution of the Neoss implant system: A retrospective follow-up of three patient cohorts treated with three types of Neoss implants. *Letters Implant Dent*. 2017;1:35–37
16. Reissmann DR, Dard M, Lamprecht R, Struppek J, Heydecke G. Oral health-related quality of life in subjects with implant-supported prostheses: A systematic review. *J Dent*. 2017;65:22–40

# Lateral sinus membrane elevation for graftless bone augmentation at Neoss implants in the atrophied posterior maxilla. A retrospective multi-centre survey

Luca Pagliani<sup>1</sup>, Roberto Romano<sup>2</sup>, Nicola Sgaramella<sup>3</sup>, Axel Andersson<sup>4,5</sup>, Peter Andersson<sup>4,5</sup>, Damiano Verrocchi<sup>5</sup>, Lars Sennerby<sup>4</sup>, Stefan Lundgren<sup>6</sup>

<sup>1</sup> Private practice, Milano, Italy

<sup>2</sup> Private practice, Palermo, Italy

<sup>3</sup> Consultant, Dept of Oral & Maxillofacial Surgery, Mater Dei Hospital Bari, Italy

<sup>4</sup> Clinica Feltre, Feltre, Italy

<sup>5</sup> Private practice, Fiera di Primiero, Italy

<sup>6</sup> Dept of Oral & Maxillofacial Surgery, Umeå University, Umeå, Sweden

*This paper presents the results from a multi-centre survey on a graftless lateral sinus membrane elevation technique to enable implant treatment in the atrophied posterior maxilla. A survival rate of 97.7% was seen based on 210 implants in 129 patients. It was shown that a surgically prepared space contained by the sinus membrane and sinus floor results in predictable bone formation, implant integration and good clinical outcomes.*

## INTRODUCTION

The edentulous atrophied posterior maxilla constitutes a challenge for the clinical team when considering prosthetic rehabilitation with dental implants in the area. One of the most common approaches to enable placement and integration of implants in this situation is to perform a sinus floor augmentation procedure with bone grafts or bone substitutes through a lateral bone window prior to or in conjunction with implant placement.<sup>1,2</sup> However, numerous clinical and experimental studies have demonstrated that the mere elevation of the sinus membrane in conjunction with implant placement will result in predictable bone formation.<sup>2,3</sup>

The sinus membrane elevation technique as described by Lundgren et al (2004) involves the preparation of a replaceable bone window in the lateral aspect of the maxillary sinus, careful elevation of the membrane, placement of implants and replacement of the lateral bone wall.<sup>4</sup> The implants serve as tent poles and allow for formation of a

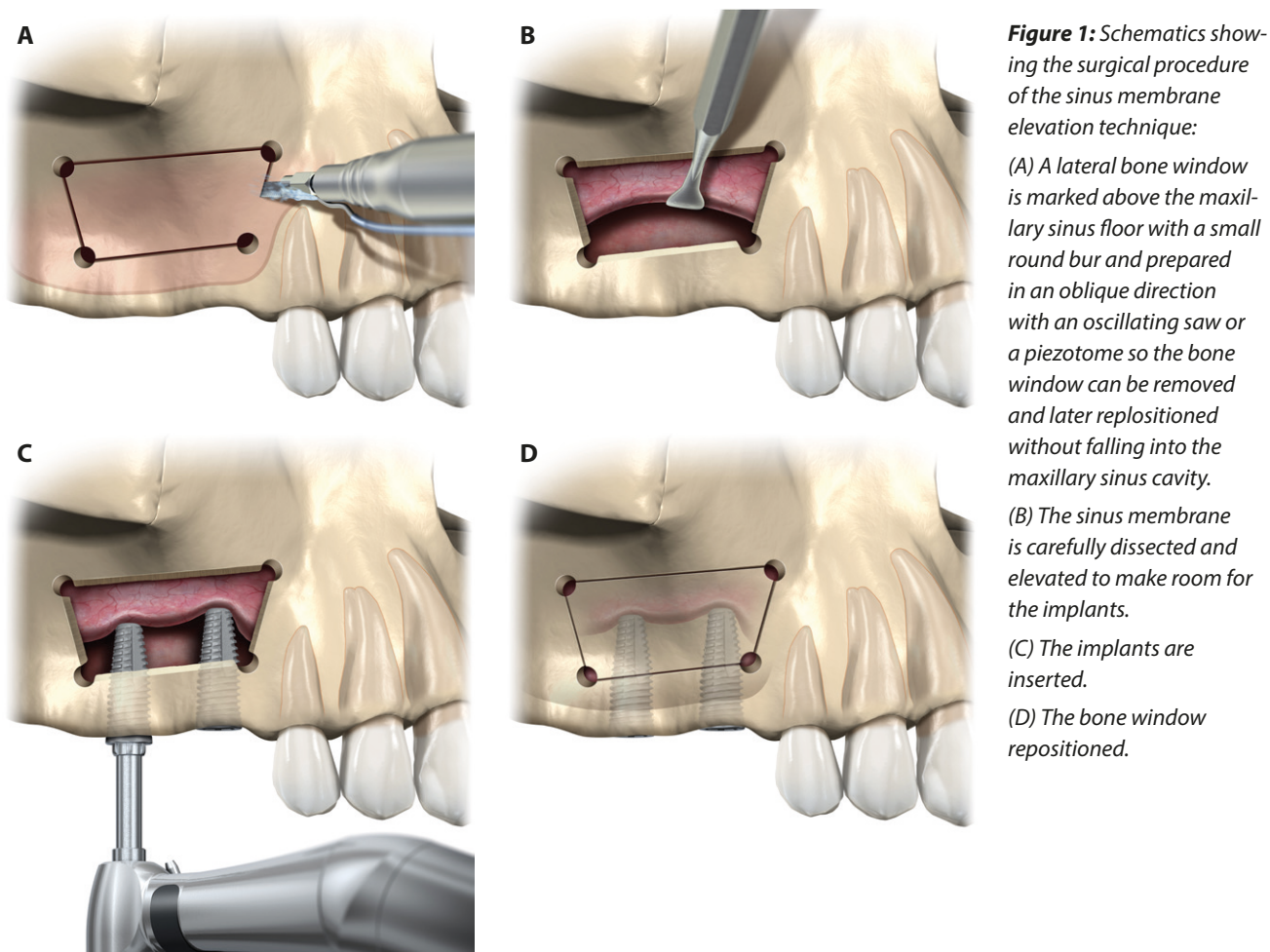
blood clot in the secluded space formed by the elevated membrane and replaced bone wall according to the principles of guided bone formation.<sup>5</sup> The most critical factors granting for successful clinical outcomes with the technique are related to the possibility to obtaining primary implant stability and rapid implant integration with the newly formed bone prior to loading.

The aim of this retrospective multi-centre survey was to evaluate the sinus membrane elevation technique when using Neoss implants.

## MATERIALS & METHODS

### Subjects

Surgeons at four clinical centres were invited to provide with data from consecutive patients missing one or several teeth in the atrophied posterior maxilla and treated with the sinus membrane elevation technique according to Lundgren et al and Neoss implants. The anonymized data were extracted from the patient charts at each clinic and



entered a spread sheet for further analysis (MS Excel, Microsoft, Redmond, USA). Information about gender, age, extent of edentulousness, bone conditions, type and number of implants, tooth position, implant stability, type of prosthesis, follow-up time and encounter of any complications were used. The primary parameter was implant failure. The study followed the World Medical Association Declaration of Helsinki and the directives given by the local ethical committee at the Feltre Hospital, Feltre, Italy.

*Sinus membrane elevation technique*

The sinus membrane elevation technique is recommended for single or multiple implants when the residual bone height below the maxillary sinus is less than the intended length of the implant(s) and that sufficient primary im-

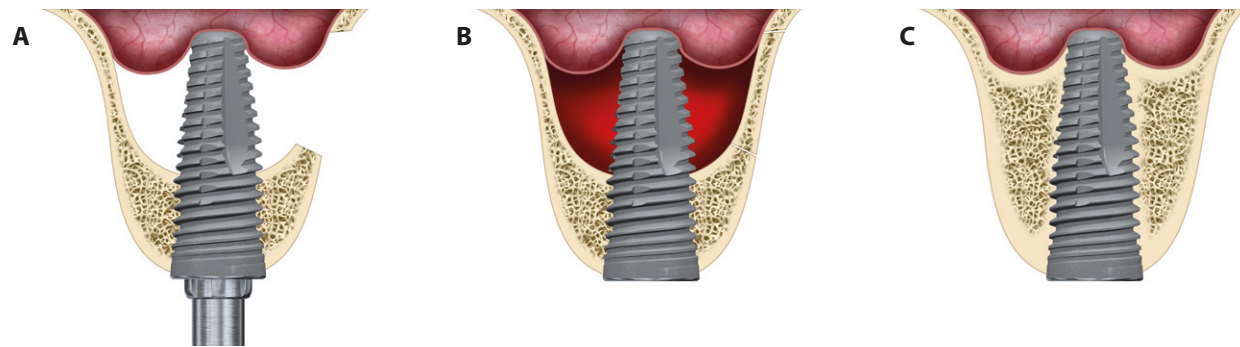
Parameter	Group	n	%
Age	Mean: 56.5 ± 9.8 years Range: 20 – 74 years	129	–
Gender	Female Male	75 54	58.1 41.9

**Table 1:** Patient demographics

plant stability can be provided. In brief, the alveolar crest and lateral bone wall of the area is exposed by a buccal muco-periosteal flap. A lateral bone window is marked above the maxillary sinus floor with a small round bur and prepared in an oblique direction with an oscillating saw or a piezotome so the bone window can be replaced without falling into the maxillary sinus cavity (Figures 1A). The sinus membrane is carefully dissected and elevated to

Parameter	Group	n	%
Implant position	First premolar	4	2.0
	Second premolar	42	20.6
	First molar	108	52.9
	Second molar	50	24.5
Implant type	Straight	118	56.2
	Tapered	92	43.8
Implant surface	ProActive	207	98.6
	Bimodal	3	1.4
Residual bone	4.5 + 2.2 mm	96	–
Implant stability	ISQ: 65.9 ± 9.5 ISQ	62	–
	IT: 35.0 ± 14.2 Ncm	50	–

**Table 2:** Baseline parameters



**Figure 2:** Schematics showing (A) an implant under the elevated membrane, (B) a blood clot is filling the contained space which eventually will be transformed into bone tissue (C).

make room for the implants (Figure 1B). The implants are inserted (Figure 1C), and the bone window repositioned (Figure 1D). If needed, the bone window can be secured with bone glue. The buccal flap is mobilized to make sure there is minimal tension over the implant cover screws and stitched. A healing period of about 6 months is used for bone formation in the contained space inside the maxillary sinus (Figure 2).

## RESULTS

Four clinical centres provided data from 129 consecutive patients (75 female, 54 male, mean age  $56.5 \pm 9.8$  years) (Table 1) treated with 210 implants, in lengths between 9 and 13 mm (Neoss, Gothenburg, Sweden) (Table 2).

At surgery, the average residual bone height below the maxillary sinus floor was  $4.5 \pm 2.2$  mm ( $n = 96$ ) with a range from 0.5 to 10.5 mm. Primary implant stability measurements showed  $35.0 \pm 14.2$  Ncm ( $n = 50$ ) and  $65.9 \pm 9.5$  ISQ ( $n = 62$ ). The implants had been restored after  $6.7 \pm 1.7$  months.

A total of five implants failed giving a survival rate of 97.7% after mean follow-up of  $5.1 \pm 2.9$  years (Table 3). Four were early failures and discovered during the initial healing period ( $n = 1$ ), at or shortly after abutment connection surgery ( $n = 3$ ). One implant failed after 2.5 years of loading (Table 4). Although not quantified, predictable bone formation was observed at the implants (Fig. 3, 4, 5).

Time interval	Implants	Failed	Withdrawn / Not followed	CSR
Insert. – 1 year	210	4	26	98.1%
1 – 2 years	180	0	14	98.1%
2 – 3 years	166	1	28	97.6%
3 – 4 years	137	0	19	97.6%
4 – 5 years	118	0	25	97.6%
5 – 6 years	93	0	23	97.6%
6 – 7 years	70	0	30	97.6%
7 – 8 years	40	0	20	97.6%
8 – 9 years	20	0	6	97.6%
9 – 10 years	14	0	3	97.6%
10 – 11 years	11	0	0	97.6%
11 – 12 years	11	0	4	97.6%
12 – 13 years	7	0	7	97.6%
13 years	0	–	–	–

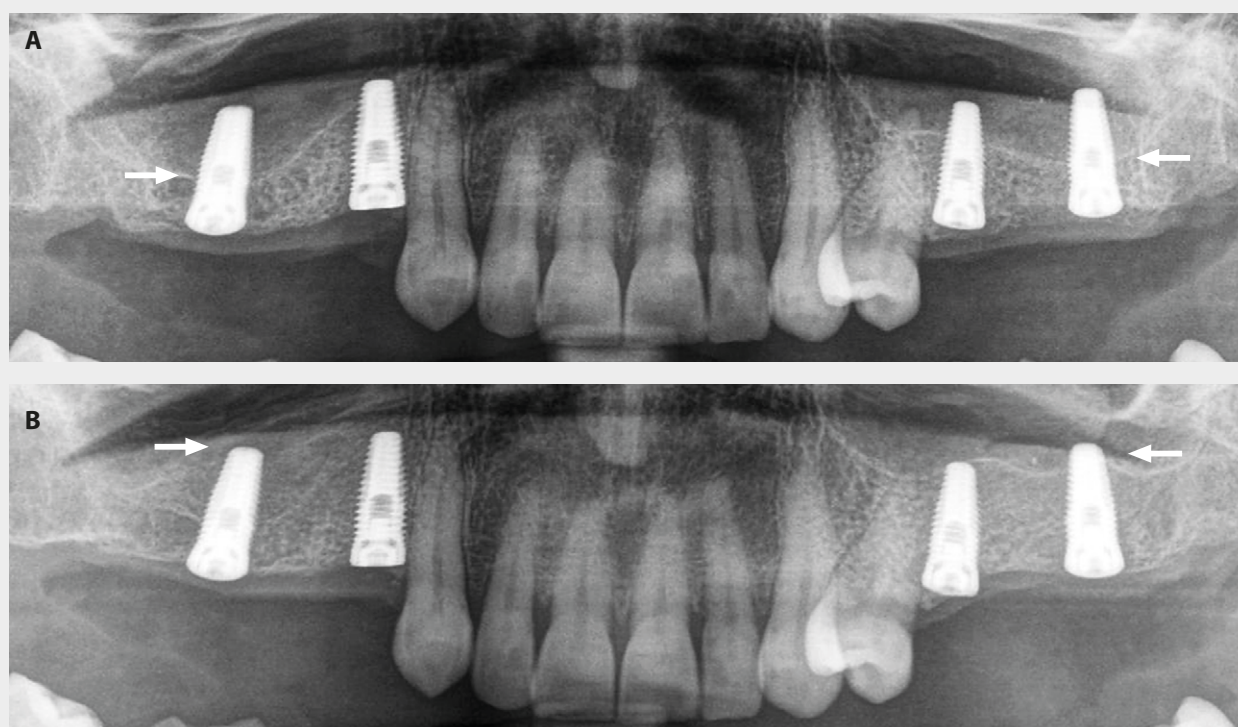
**Table 3:** Life table

## DISCUSSION

The present retrospective survey of patients from four different clinics demonstrated that the Neoss implant designs performed very well in extremely challenging bone situations in the atrophied posterior maxilla. The implant

Pat. ID	Gender	Age	Position	Implant type	Dimensions	Residual height
16	Male	54	First molar	ProActive Straight	$4.0 \times 11$ mm	–
50	Male	51	Second premolar	ProActive Straight	$4.0 \times 11$ mm	–
55	Male	47	First molar	ProActive Tapered	$4.0 \times 13$ mm	3.9
81	Female	52	Second premolar	ProActive Tapered	$4.5 \times 9$ mm	3
125	Male	53	Second premolar	ProActive Straight	$4.0 \times 9$ mm	–

**Table 4:** Specification of failed implants



**Figure 3:** OPTs of a bilateral case. (A) Immediate postoperative view. Arrows indicating the position of the sinus floor. (B) View after 6 months of healing. Arrows indicating the position of the sinus floor.

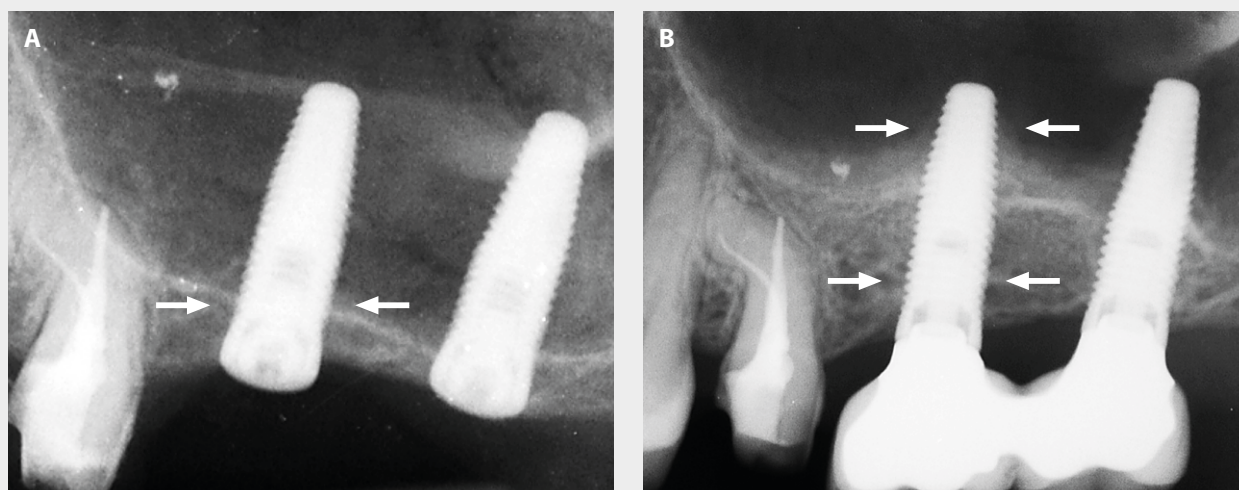
survival rate of 97.7% is in line with what has been reported when using sinus membrane elevation with other modern implant designs.<sup>2,3</sup> Although no attempts were made to quantify the amount of new bone formation in the present survey, our experiences are in line with those of other authors who reported predictable formation of bone at the implants.<sup>6,7</sup>

Four of five failures occurred shortly after implant placement and indicates that primary implant stability and proper implant integration is the major critical factor for a good outcome. In this respect, the implant surface properties are important.<sup>8</sup> The ProActive surface provokes a strong bone tissue response when compared with other commercial implants, which seems to relate to its moderate roughness.<sup>9</sup> Although not yet proven, also the hydrophilicity may further facilitate integration.

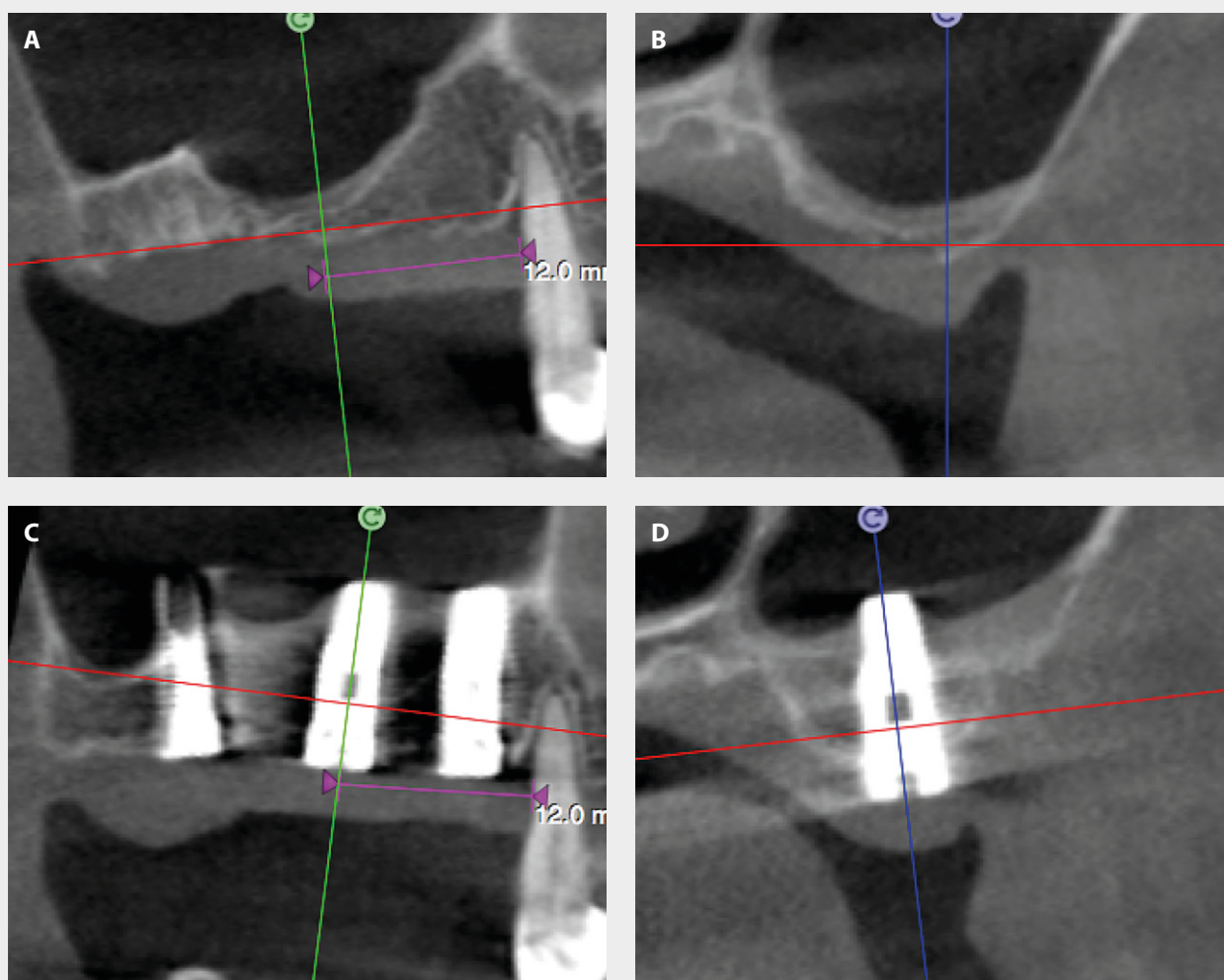
An in vitro study has demonstrated better stability for Neoss Tapered than for Neoss Straight implants, which both were used in the present study.<sup>10</sup> However, our data showed that sufficient primary stability could be obtained with both designs and no differences were observed in survival rate. Nonetheless, there might be other benefits with the tapered design as the implant has a short conical neck with threads up on the collar. It needs no or less counter sinking, which means that most of a small bone volume can be used for stabilization of the implant. In addition,

it gives a lower profile after placement with less titanium protruding into the overlying mucosa as compared to a non-submerged Straight design. This implies less risk for premature loading, implant exposure, and subsequent bone resorption, which is an event that should be avoided as the implants are placed in scarce amount of bone.

The graftless membrane elevation technique challenges the idea that the maxillary sinus floor has to be augmented with bone grafts or bone substitutes to enable integration of implants. However, this and many other studies show that a surgically prepared space contained by the sinus membrane and sinus wall will result in predictable bone formation, implant integration and good clinical outcomes. The technique is low invasive and cost effective from a patient point of view.



**Figure 4:** Postoperative intraoral radiographs of a left maxilla. (A) After implant placement of two Neoss ProActive Tapered implants. Arrows indicating position of the sinus floor. (B) The same implants at follow-up after 3 years. Arrows indicating the baseline and present position of the sinus floor.



**Figure 5:** CBCTs of a right maxillary case. (A) Preoperative view in mesio-distal direction. (B) Bucco-palatal 90 degree view of the section indicated by the vertical green line in A. (C, D) The same area 11 months after surgery with three Neoss ProActive Straight implants. Note marked bone formation around the implants.

## REFERENCES

1. Boyne PJ, James RA. Grafting of the maxillary sinus floor with autogenous marrow and bone. *J Oral Surg.* 1980;38:613–616
2. Lundgren S, Cricchio G, Hallman M, Jungner M, Rasmusson L, Sennerby L. Sinus floor elevation procedures to enable implant placement and integration: techniques, biological aspects and clinical outcomes. *Periodontol 2000.* 2017;73:103–120
3. Lie SAN, Claessen RMMA, Leung CAW, Merten HA, Kessler PAWH. Non-grafted versus grafted sinus lift procedures for implantation in the atrophic maxilla: a systematic review and meta-analysis of randomized controlled trials. *Int J Oral Maxillofac Surg.* 2022;51:122–132
4. Lundgren S, Andersson S, Gualini F, Sennerby L. Bone reformation with sinus membrane elevation: a new surgical technique for maxillary sinus floor augmentation. *Clin Implant Dent Relat Res.* 2004;6:165–173
5. Jungner M, Cricchio G, Salata LA, Sennerby L, Lundqvist C, Hultcrantz M, Lundgren S. On the Early Mechanisms of Bone Formation after Maxillary Sinus Membrane Elevation: An Experimental Histological and Immunohistochemical Study. *Clin Implant Dent Relat Res.* 2015;17:1092–1102
6. Cricchio G, Sennerby L, Lundgren S. Sinus bone formation and implant survival after sinus membrane elevation and implant placement: a 1- to 6-year follow-up study. *Clin Oral Implants Res.* 2011;22:1200–1212
7. Lundgren S, Johansson AS, Cricchio G, Lundgren S. Clinical outcome and factors determining new bone formation in lateral sinus membrane elevation with simultaneous implant placement without grafting material: A cross-sectional 3–17 year follow up study. *Clin Implant Dent Relat Res.* 2019;21:827–834
8. Palma VC, Magro-Filho O, de Oliveria JA, Lundgren S, Salata LA, Sennerby L. Bone reformation and implant integration following maxillary sinus membrane elevation: an experimental study in primates. *Clin Implant Dent Relat Res.* 2006;8:11–24
9. Sennerby L, Gottlow J, Gottlow J. Integration of Neoss ProActive implants in comparison with other brands of dental implants. *Letters Implant Dent* 2017;1:7–20
10. Sennerby L, Pagliani L, Petersson A, Verrocchi D, Volpe S, Andersson P. Two different implant designs and impact of related drilling protocols on primary stability in different bone densities: an in vitro comparison study. *Int J Oral Maxillofac Implants.* 2015;30:564–568

# Short implants for single tooth replacement in limited bone volumes in the posterior maxilla

Stefano Volpe<sup>1</sup>, Michele Di Girolamo<sup>1,2</sup>, Peter Andersson<sup>3,4</sup>, Damiano Verrocchi<sup>3</sup>, Lars Sennerby<sup>4</sup>

<sup>1</sup> Private Practice, Rome, Italy

<sup>2</sup> Dept Periodontology, Tor Vergata University of Rome, Italy

<sup>3</sup> Private practice, Fiera di Primiero, Italy

<sup>4</sup> Clinica Feltre, Feltre, Italy

*This study evaluates the survival rate of 9 mm long single implants placed under the maxillary sinus with or without the use of a transcrestal osteotome technique due to insufficient vertical bone height. No difference in survival rate was found based on 231 implants in 210 patients after 1 to 12 years of function.*

## INTRODUCTION

The early experiences with machined dental implants showed that short implants (<10 mm) were prone to implant failure and particularly in soft bone.<sup>1,2</sup> Therefore, clinicians have hesitated to use short implants in the posterior maxilla and often performed a lateral sinus lift procedure with bone grafts to enable placement of longer implants (>10 mm). Clinical studies of modern surface-modified implants have revealed similar survival rates for short and long implants when including all indications.<sup>3</sup> This is most likely due to the faster and stronger bone response to such surfaces compared with the old, machined ones, as demonstrated in animal experiments.<sup>4</sup> However, studies have also indicated that short maxillary implants may be less successful than mandibular ones.<sup>5</sup>

If the residual bone height is less than the length of the implant, many clinicians still consider making an invasive lateral sinus lift procedure prior to or in conjunction with implant placement. The present authors have been using various non-invasive transcrestal graft-free procedures in conjunction with implant placement with good results.<sup>6,7</sup> The technique is used in sites with 4 to 7 mm of residual bone under the sinus and involves elevation of the sinus floor and/or the sinus membrane with an osteotome.<sup>8</sup>

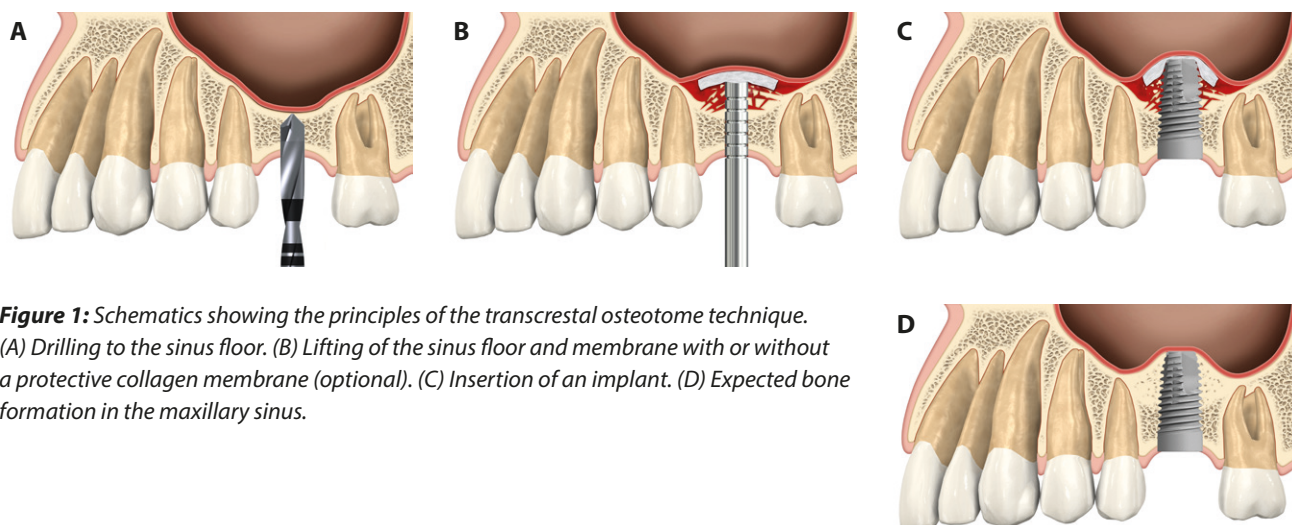
The present retrospective study evaluated the survival rate of 9 mm Neoss ProActive implants placed in posterior maxillary tooth gaps with or without the use of a transcrestal sinus floor elevation technique.

## MATERIALS & METHODS

### *Patients and data collection*

The present retrospective chart study included data from consecutive patients treated in three dental clinics. The inclusion criterion was previous placement of 9 mm long Neoss ProActive implants (Neoss, Gothenburg, Sweden) in maxillary tooth gaps in second premolar or molar sites. Information about gender, time of surgery, additive surgical procedures, implant type, implant stability as measured with resonance frequency analysis (RFA) measurements, follow-up and possible complications were extracted from the patient charts and analysed. The study followed the World Medical Association Declaration of Helsinki and the directives given by the local ethical committee at the Feltre Hospital, Feltre, Italy.

A total of 210 patients (132 female, 78 male, mean age  $43.7 \pm 12.5$  years) treated with 231 nine mm long implants over a period of 13 years met with the inclusion criterion.



**Figure 1:** Schematics showing the principles of the transcresal osteotome technique. (A) Drilling to the sinus floor. (B) Lifting of the sinus floor and membrane with or without a protective collagen membrane (optional). (C) Insertion of an implant. (D) Expected bone formation in the maxillary sinus.

Two implant designs had been used: Neoss Straight ( $n=160$ ) and Neoss Tapered ( $n=71$ ) implants in diameters from 3.25 to 6 mm (Table 1). The 9 mm implants had been placed in sufficient bone volumes using the normal protocol ( $n=152$ ) or with the use of an osteotome technique for transcresal sinus floor augmentation in sites where the residual bone height was 4 to 7 mm ( $n=79$ ) as described elsewhere (Figure 1).<sup>7</sup>

Parameter	Group	ProActive Straight	ProActive Tapered	All
Implant length	9 mm	160	71	231
Implant diameter	3.25 mm	1	–	1
	3.5 mm	6	1	7
	4.0 mm	72	47	119
	4.5 mm	60	6	66
	5.0 mm	21	16	37
	6.0 mm	–	1	1
Surgical technique	Normal	119	33	152
	Osteotome	41	38	79

**Table 1:** Implant characteristics

Implant type	Group	ISQ 1	ISQ 2
All implants	All	74.2 ± 6.4	76.0 ± 4.4
Straight	All	74.0 ± 6.6	75.4 ± 4.1
	Normal	74.5 ± 6.7	75.6 ± 4.1
	Osteotome	72.6 ± 6.2	74.7 ± 4.1
Tapered	All	74.3 ± 6.0	76.8 ± 4.6
	Normal	74.6 ± 5.3	76.6 ± 4.8
	Osteotome	74.1 ± 6.6	77.0 ± 4.3

**Table 2:** Implant stability at insertion (ISQ1) and after healing (ISQ2)

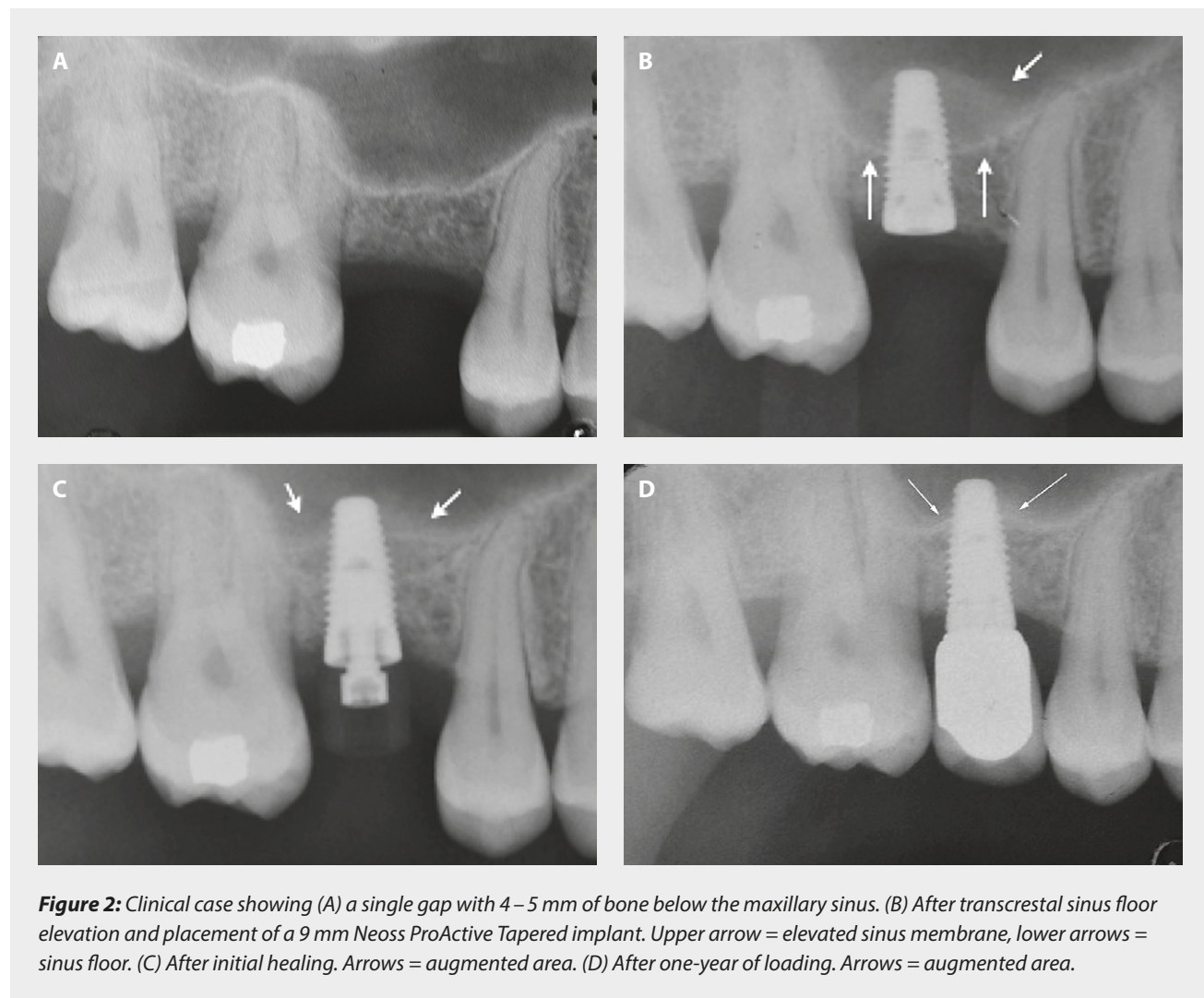
## RESULTS

Firm primary stability was achieved, which increased during the initial healing period from  $74.2 \pm 6.4$  ISQ to  $76.0 \pm 4.4$  ISQ (Table 2). Small differences were seen between the two implant designs with a tendency of higher secondary stability for the Neoss Tapered implant. The Neoss Straight implants placed with the osteotome technique showed lower primary and secondary stability than the other sub-groups.

A total of nine implant failures (3.9%) in nine patients (4.3%) had been registered (Table 3 and 4). Four were early failures before loading (1.7%) and five were late failures (2.2%). Hence, the CSR was 96.1% after a mean follow-up

Time interval	Implants	Failed	Withdrawn / Not followed	CSR
Insert. – 1 year	231	4	14	98.3%
1 – 2 years	213	0	24	98.3%
2 – 3 years	189	0	21	98.3%
3 – 4 years	168	2	21	97.4%
4 – 5 years	145	0	20	97.4%
5 – 6 years	125	0	13	97.4%
6 – 7 years	112	1	26	97.0%
7 – 8 years	85	1	9	96.5%
8 – 9 years	75	0	24	96.5%
9 – 10 years	51	1	25	96.1%
10 – 11 years	25	0	16	96.1%
11 – 12 years	9	0	7	96.1%
12 years	2	–	–	–

**Table 3:** Life table

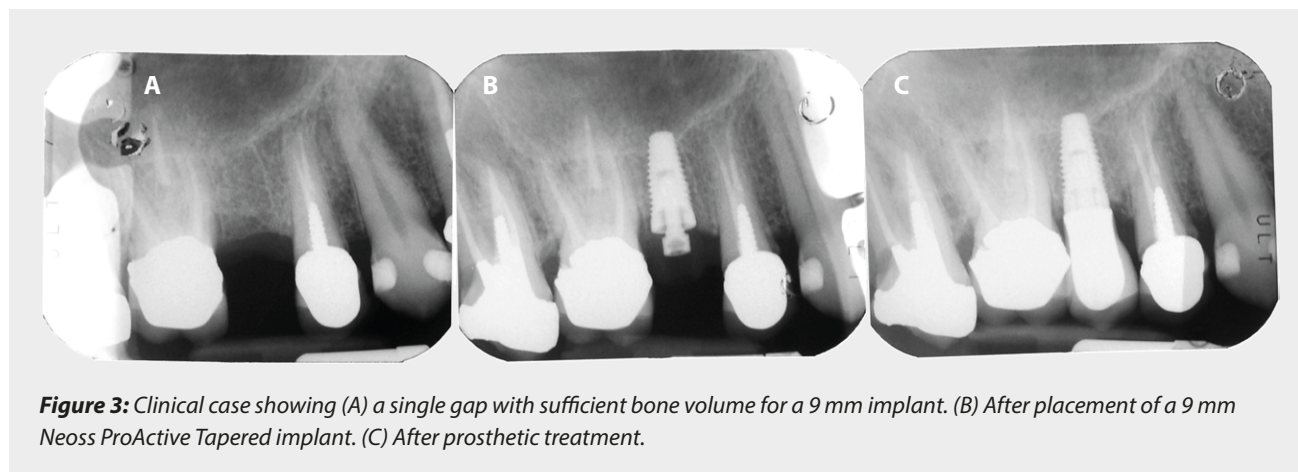


of  $5.4 \pm 3.4$  years (range 1 to 12 years). Six failures occurred in the normal placement group (3.9%) and three in the osteotome group (3.8%).

The early failures showed lower primary stability than the overall mean value, 69.3 vs 74.2 ISQ, while the late failures showed high stability, 75.6 vs 74.2 ISQ.

Gender	Age	Position	Type	Diameter	Placement	ISQ	Failure time	Failure type
Male	73	First molar	Tapered	4.0	Osteotome	74	2 weeks	Early
Male	68	Second premolar	Tapered	4.0	Osteotome	64	1 month	Early
Female	51	Second premolar	Straight	4.0	Normal	60	2 months	Early
Female	66	First molar	Straight	3.5	Normal	79	4 months	Early
Female	63	First molar	Straight	5.0	Normal	82	3 years	Late
Male	37	Second premolar	Tapered	4.0	Normal	75	3 years	Late
Male	38	Second premolar	Tapered	4.5	Normal	82	6 years	Late
Female	39	Second premolar	Straight	4.0	Normal	75	7 years	Late
Male	64	First molar	Tapered	5.0	Osteotome	64	9 years	Late

**Table 4:** Specification of failed implants



## DISCUSSION

The present retrospective analysis showed no differences when comparing the stability and survival rate for 9 mm Neoss ProActive implants placed with or without an osteotome technique in the posterior maxilla. This is in line with other studies<sup>5</sup> and confirms that the non-invasive osteotome technique is an effective means to place implants in reduced bone volumes under the maxillary sinus.<sup>5,10</sup> Although not quantified, predictable bone formation around the implant apices was seen, as reported elsewhere.<sup>6,7</sup>

The overall 5-year survival rate of 96.1% is slightly lower than the 97.5% reported in previous clinical studies including all lengths of Neoss ProActive implants.<sup>9</sup> More late than early failures were seen in the present study, which probably reflected the long-term biomechanical challenges that short implants face in the posterior maxilla, i.e., the combination of soft bone, high bite force and use of wide/high crowns.<sup>5</sup>

The present study indicated that:

- short implants can be successfully used in the posterior maxilla with or without the use of an transcrestal osteotome technique,
- invasive sinus floor augmentation procedures are not necessary in single tooth gaps with >4 mm of residual bone below the maxillary sinus.

## REFERENCES

1. Friberg B, Jemt T, Lekholm U. Early failures in 4,641 consecutively placed Brånemark dental implants: a study from stage 1 surgery to the connection of completed prostheses. *Int J Oral Maxillofac Implants.* 1991;6:142-146
2. Sennerby L, Roos J. Surgical determinants of clinical success of osseointegrated oral implants: a review of the literature. *Int J Prosthodont.* 1998;11:408-420
3. Andersson P, Pagliani L, Verrocchi D, Volpe S, Sahlin H, Sennerby L. Factors Influencing Resonance Frequency Analysis (RFA) Measurements and 5-Year Survival of Neoss Dental Implants. *Int J Dent.* 2019;3209872
4. Burgos PM, Rasmusson L, Meirelles L, Sennerby L. Early bone tissue responses to turned and oxidized implants in the rabbit tibia. *Clin Implant Dent Relat Res.* 2008;10:181-190
5. Ravidà A, Majzoub J, Alassadi M, Saleh MH, Askar H, Wang HL. Impact of Implant Length on Survival of Rough-Surface Implants in Nonaugmented Posterior Areas: A Systematic Review and Meta-Regression Analysis. *Int J Oral Maxillofac Implants.* 2019;34:1359-1369
6. Volpe S, Lanza M, Verrocchi D, Sennerby L. Clinical outcomes of an osteotome technique and simultaneous placement of Neoss implants in the posterior maxilla. *Clin Implant Dent Relat Res.* 2013;15:22-28
7. Volpe S, Di Girolamo M, Pagliani P, Zicari S, Sennerby L. Osteotome-Induced Blood Clot and Subsequent Bone Formation with the Use of Collagen Sponge for Integration of Single Dental Implants into the Atrophied Posterior Maxilla: A Retrospective Follow-Up of 36 Implants after 5 to 13 years. *Int J Dent.* 2022;6594279
8. Summers RB. The osteotome technique: Part 3. Less invasive methods of elevating the sinus floor. *Compendium.* 1994;15:698-704
9. Sahlin H. Implant survival, bone remodeling and implant stability of Neoss implants: a systematic review of the literature. *Letters Implant Dent.* 2017;1;15-20
10. Del Fabbro M, Corbella S, Weinstein T, Cerasoli V, Taschieri S. Implant survival rates after osteotome-mediated maxillary sinus augmentation: a systematic review. *Clin Implant Dent Relat Res.* 2012;14(S1):e159-e168

# Single tooth restorations on Neoss ProActive Straight implants in healed sites and extraction sockets. A retrospective survival analysis

Pierluigi Coli<sup>1</sup>, Lars Sennerby<sup>2</sup>

<sup>1</sup> Edinburgh Dental Specialists, Edinburgh, UK

<sup>2</sup> Clinica Feltre, Feltre, Italy

*A retrospective analysis of 303 single tooth replacement (Neoss ProActive Straight) in 240 patients showed an overall survival rate of 97.1% after a follow up of 1 to 8 years. There were no failures for implants placed in conjunction with tooth extraction.*

## INTRODUCTION

Implant dentistry is an integrated part of many modern dental clinics, which offer implants as a first-choice treatment modality to replace missing teeth.<sup>1</sup> The single tooth gap is the most common indication for this type of treatment and is anticipated as easy and suitable for the beginner.<sup>2</sup> The safest and most common protocol is to allow the carefully cleaned extraction socket to heal for 3 to 6 months prior to surgical placement of an implant when bone will be reformed, and possible infections cleared. Implant placement in conjunction with tooth extraction is an attractive treatment modality to shorten the overall treat-

ment time.<sup>3</sup> However, this is a more challenging situation from a surgical and biological point of view with regard to reaching correct implant position, firm primary stability, and management of remaining defects around the implant.

This retrospective chart study reports on the survival rate of 303 consecutive single tooth replacements in 240 patients after 1 to 8 years of clinical function. The implants had been placed in both healed sites and extraction sockets with or without adjunct bone substitutes.

## MATERIALS & METHODS

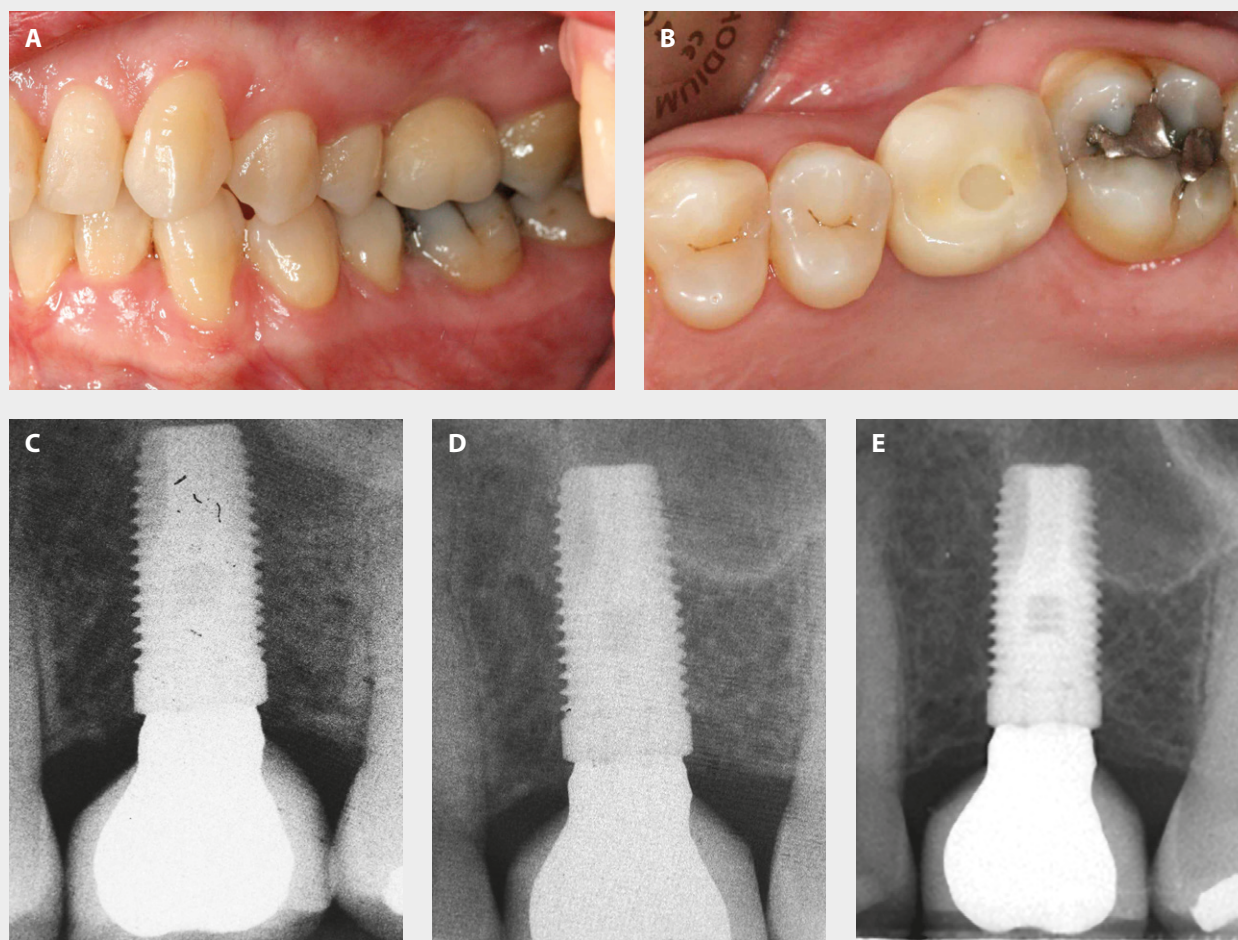
### *Patients and data collection*

Consecutive patients previously treated with implant-supported (ProActive Straight, Neoss, Gothenburg, Sweden) single crowns at the Edinburgh Dental Specialist referral clinic, Edinburgh, Scotland were identified. Data relating to treatments including implant placement in healed gaps as well as in conjunction with tooth extraction were extracted from the patients' charts and analyzed. The study was made in accordance with the World Medical Association Declaration of Helsinki.

A total of 240 patients (136 female, 104 male, mean age  $58.3 \pm 12.6$  years, range 19 to 89 years) treated with 303 implants and single crowns were found and included in the study (Table 1). A total of 202 implants had been

Parameter	Group	n	%
Implant position	Anterior maxilla	88	29.0
	Posterior maxilla	114	37.6
	Anterior mandible	4	1.3
	Posterior mandible	97	32.0
Jaw	Maxilla	202	66.7
	Mandible	101	33.3
Surgical protocol	One-stage	295	97.4
	Two-stage	8	2.6
Site type	Healed	226	74.6
	Extraction socket	77	25.4
	– whereof augmented	32	41.6

**Table 1:** Baseline parameters



**Figure 1:** Upper molar case after 6 years of loading. (A) Lateral and (B) occlusal views. (C) Intraoral radiograph at crown delivery. (D) After one year. (E) After 6 years of function.

placed in the maxilla and 101 in the mandible in lengths of 7 to 13 mm and 3.25 to 5.0 mm in diameter (Table 2). The posterior maxilla was the most common area for implant placement ( $n=114$ ), followed by the posterior mandible ( $n=97$ ), anterior maxilla ( $n=88$ ) and anterior mandible ( $n=4$ ) (Table 1). Most implants were placed in healed gaps ( $n=226$ ) and 77 in immediate extraction sockets, where bone grafts (BioOss) had been added to 32 sockets (Table 1). A one-stage procedure had been used for 295 implants, while eight implants healed under the mucosa (Table 1).

Number of implants		Implant diameter (mm)					Total
		3.25	3.5	4.0	4.5	5.0	
Implant length	7 mm	–	–	1	–	–	1
	9 mm	–	5	29	32	14	80
	11 mm	4	26	44	45	13	132
	13 mm	4	23	51	12	–	90
	Total	8	54	125	89	27	303

**Table 2:** Distribution of implants by implant length and diameter

The final crown was delivered on average  $4.7 \pm 2.5$  months after surgery.

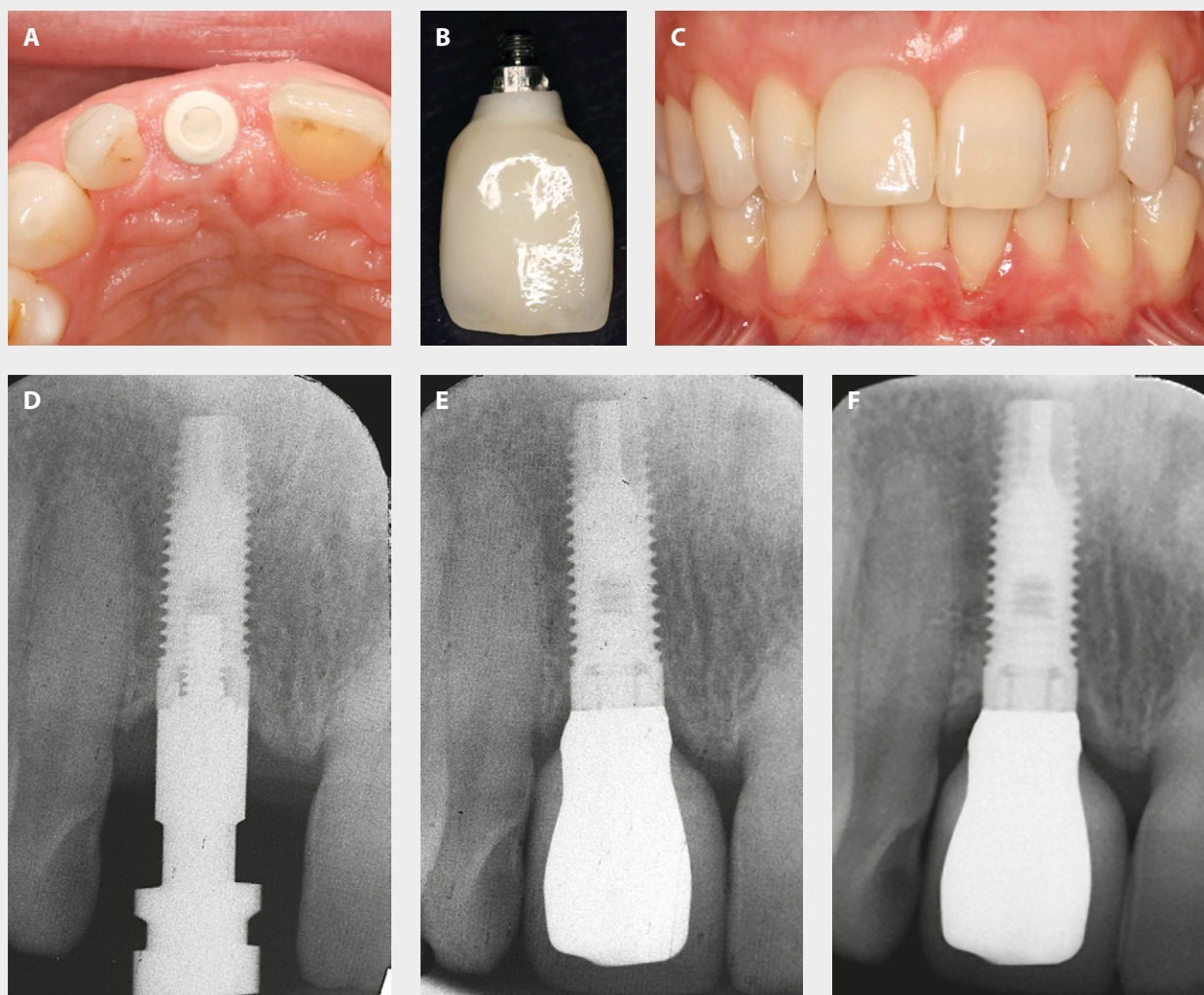
#### Follow-ups

A follow-up appointment was carried out after 3–4 weeks and patients were thereafter scheduled for recalls once a year the first two years, thereafter at the fifth, seventh, 10th anniversary and every 2–3 years thereafter. At these appointments, assessments of the stability of the crown and of the soft and hard peri-implant tissues conditions by clinical and radiographic examinations were carried out.

#### RESULTS

A total of eight implants failed in eight patients giving a cumulative survival rate of 97.1% (Table 3) after a mean follow-up of  $4.2 \pm 1.9$  years (range 1–8 years).

Six failures occurred before prosthetic treatment due to infection ( $n = 5$ ) and non-integration ( $n = 1$ ). Two implants were lost 37 and 47 months after treatment due to peri-apical infections. No failures were seen for immediate



**Figure 2:** (A) Upper central incisor case after 3 months of one-stage healing with a PEEK healing abutment. (B) Final crown. (C) Clinical appearance after 3 months. (D) Intraoral radiograph at time of impression, (E) after fit of final crown, (F) after 5 years of function

placements in extraction sockets (Table 4). The highest failure rate was seen in the posterior mandible (5.2%) followed by the posterior (1.8%) and anterior (1.1%) maxilla. All failed implants were replaced with new ones after, on average,  $2.6 \pm 2.2$  months and the treatment could eventually be completed in all patients.

The marginal bone levels were maintained throughout the observation period, although not quantified in the present study.

## DISCUSSION

The present survival analysis of 303 single tooth replacements with Neoss ProActive Straight implants showed a CSR of 97.1% after 1 to 8 years of function. This is in line with previous studies on Neoss and other implant systems.<sup>4,5</sup> Apart from the failures, there were few other complications related to crown stability, soft tissue health or marginal bone levels.

Implant failure is not a terminal event like the loss of a tooth and a new implant can in most instances replace

Time interval	Implants	Failed	Withdrawn / Not followed	CSR
Insert. – 1 year	303	6	0	98.0%
1 – 2 years	297	0	17	98.0%
2 – 3 years	280	0	67	98.0%
3 – 4 years	213	2	62	97.1%
4 – 5 years	149	0	52	97.1%
5 – 6 years	97	0	37	97.1%
6 – 7 years	60	0	21	97.1%
7 – 8 years	39	0	27	97.1%
8 years	12	–	–	–

**Table 3:** Life table

ID	Gender	Age	Position	Dimensions	Site	Surgical protocol	Failure time	Reason
1	Male	65	Lower molar	5.0 × 11 mm	Healed	One-stage	2 months	Infection
2	Female	51	Lower molar	4.5 × 9 mm	Healed	One-stage	37 months	Root remnants
3	Male	65	Upper molar	5.0 × 11 mm	Healed	One-stage	47 months	Infection
4	Male	66	Upper premolar	4.5 × 11 mm	Healed	One-stage	4 months	Infection
5	Female	63	Lower molar	4.0 × 9 mm	Healed	One-stage	3 months	Infection
6	Male	51	Lower molar	4.0 × 11 mm	Healed	One-stage	3 months	Infection
7	Female	32	Lower molar	4.5 × 11 mm	Healed	One-stage	4 months	Non-integrated
8	Male	30	Upper lateral incisor	3.25 × 11 mm	Healed	One-stage	4 months	Infection

**Table 4:** Specification of failed implants

the failed one. In the present group of patients, the eight failed implants (2.9%) could be successfully replaced by new ones, resulting in a treatment delay of about 6 months.

The majority of referred patients in the present study presented with healed single gaps, since the teeth had been extracted elsewhere on different indications. Many tooth extractions in general practice are probably executed without proper cleaning of the socket, which is left open for secondary healing. Thus, increasing the risk of leaving behind infected tissue that can become encapsulated by newly formed bone during healing. This could explain why all failures in the present study were seen in healed sites, while no failures were seen in the cases when tooth extraction, careful socket cleaning and implant placement procedures were provided by the present surgeon.

The current trend is to use different kind of membranes and fillers to enhance socket healing to maintain bone volumes prior to or in conjunction with implant placement.<sup>6</sup> Studies have shown positive effects on some parameters related to bone volumes, but it does not seem to affect the survival rate of the implants or the soft- and hard tissue preservation parameters, at least not when placed in intact sockets in the anterior zone.<sup>7</sup> In the present study, a filler was used in extraction sockets if the buccal wall was missing. This indication seems to be justified by the results from the Zhou et al meta-analysis, since implants placed in sockets with defective buccal walls showed lower survival rates.<sup>7</sup> It is concluded that Neoss ProActive Straight implants placed in healed edentulous ridges and/or extraction sockets show high survival rates when used for single tooth replacements. Proper cleaning of the sockets prior to implant placement appears to have an important role in reducing early implant failures.

## REFERENCES

1. Buser D, Sennerby L, De Bruyn H. Modern implant dentistry based on osseointegration: 50 years of progress, current trends and open questions. *Periodontol* 2000. 2017;73:7-21.
2. Torabinejad M, Sabeti M, Goodacre CJ (eds). *Principles and practice of single implant and resorations*. Elsevier Saunders, St Louis, US, 2014
3. Chrcanovic BR, Martins MD, Wennerberg A. Immediate placement of implants into infected sites: a systematic review. *Clin Implant Dent Relat Res*. 2015;17 Suppl 1:e1-e16.
4. Sahlin H. Implant survival, bone remodeling and implant stability of Neoss implants: a systematic review of the literature. *Letters Implant Dent* 2017;1;15-20
5. Zhou W, Gallucci GO, Chen S, Buser D, Hamilton A. Placement and Loading Protocols for Single Implants in Different Locations: A Systematic Review. *Int J Oral Maxillofac Implants*. 2021;36:e72-e89.
6. Del Fabbro M, Tommasato G, Pesce P, Ravidà A, Khijmatgar S, Sculean A, Galli M, Antonacci D, Canullo L. Sealing materials for post-extraction site: a systematic review and network meta-analysis. *Clin Oral Investig*. 2022;26:1137-1154.
7. Zhou X, Yang J, Wu L, Tang X, Mou Y, Sun W, Hu Q, Xie S. Evaluation of the Effect of Implants Placed in Preserved Sockets Versus Fresh Sockets on Tissue Preservation and Esthetics: A Meta-analysis and Systematic Review. *J Evid Based Dent Pract*. 2019;19(4):101336.

# Peri-implantitis. A short and critical review

Pierluigi Coli<sup>1</sup>, Kevin Lochhead<sup>1</sup>, Lars Sennerby<sup>2</sup>

<sup>1</sup> Edinburgh Dental Specialists, Edinburgh, UK

<sup>2</sup> Clinica Feltre, Feltre, Italy

*The present narrative review discusses the notion that peri-implantitis, as diagnosed with periodontal indices, is a major threat to the longevity of a large number of dental implants. It is concluded that the unvalidated use of periodontal indices and the assumption that bleeding at probing and pocket depth over 4 mm are signs of disease cannot be supported by the scientific clinical literature. Instead, it leads to over-diagnosis, unnecessary worries and over-treatment of well-functioning dental implants.*

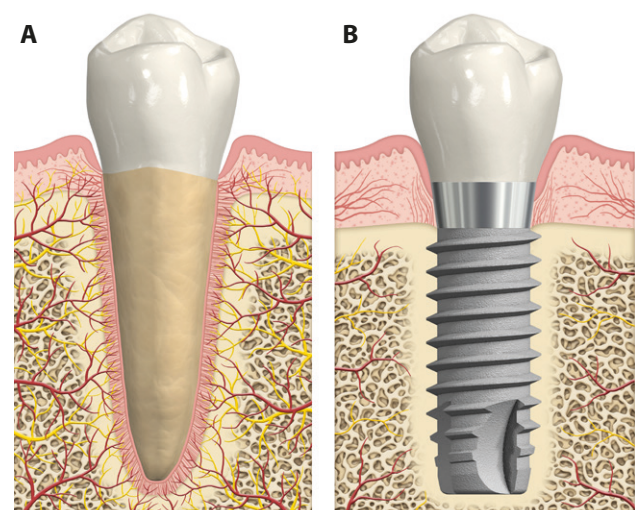
## INTRODUCTION

The use of dental implants is scientifically well documented and numerous long-term studies have shown predictable results with few serious complications.<sup>1</sup> However, there are claims that over 50% of dental implants show signs of disease when examined with periodontal indices and predictions of a future tsunami of “peri-implantitis”, i.e. severe marginal bone resorption, and subsequent implant losses.<sup>2–3</sup> Thus, the diseased implants need to be treated with non-surgical or surgical interventions to “resolve the disease”.<sup>4</sup> In an editorial, a restricted use of dental implants was advocated based on the findings from a series of studies in the same journal, showing interestingly very few failures, but still claiming high levels of peri-implant disease among a large group of patients.<sup>5–8</sup> If this was correct, the waiting rooms would be crowded by previously treated implant patients, now suffering from “peri-implantitis” as well as the literature would be dominated by clinical reports with catastrophic failure rates. On the contrary, the scientific literature demonstrates dental implants to be very successful with failure rates around 2–3% after 10 years with about 2–3% of implants affected by severe marginal bone loss and so-called peri-implantitis.<sup>9</sup>

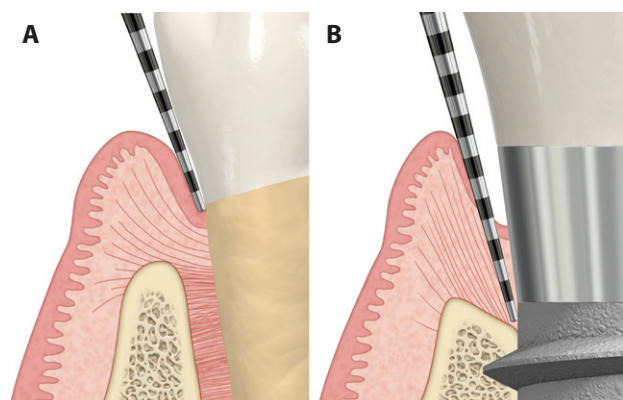
## SURROGATE ENDPOINTS

The reason for such a controversy is the use of different endpoints.<sup>10</sup> Most of the long-term clinical implant in-

vestigations have been using true endpoints, i.e. loss and removal of the implants and of the associated prosthetic restorations, whereas more recently investigations have been using surrogate endpoints, such as bleeding on probing (BoP), increased probing pocket depth (PPD) and some degree of bone loss, in the unvalidated assumption of a clear link between the surrogate endpoints and the true endpoint. One example is one of the first studies reporting on alarming levels of peri-implant disease based on BoP and bone loss occurring after the first year of



**Figure 1:** Schematics showing the morphology of (A) the dento-gingival complex and (B) the implant situation.



**Figure 2:** Schematics showing probing (A) at a healthy tooth and (B) at an implant.

function.<sup>11</sup> According to the authors, about 56% of all implants were affected by disease and had an expected poor prognosis. However, when analysing the same patient cohort 9 years later, no differences between “affected” and healthy implants with regard to implant failures could be detected.<sup>12</sup> Moreover, 91.4% of the implants in the patients diagnosed with peri-implantitis showed either no or minimal annual bone loss during the 9 years from the diagnosis. Hence, the surrogate endpoints used by the authors, namely bone loss associated with bleeding on probing, were shown to be poor predictors of future bone loss and implant failure and consequently poor indicators of treatment needs. With such a periodontal approach for the diagnosis of peri-implant diseases, there is an obvious risk that patients will be subjected to unnecessary treatment, with consequent iatrogenic and financial damages.<sup>13</sup>

### TEETH VS IMPLANTS

The periodontal complex is the result of million years of evolution and is build up by highly differentiated and specialized tissues. Osseointegration on the other hand is the result of a foreign body reaction to an implant and the soft- and bone tissue interfaces consists of lowly differentiated tissues.<sup>14–15</sup> From a morphological point of view the tooth and the implant represent two completely different entities (Figures 1 and 2).

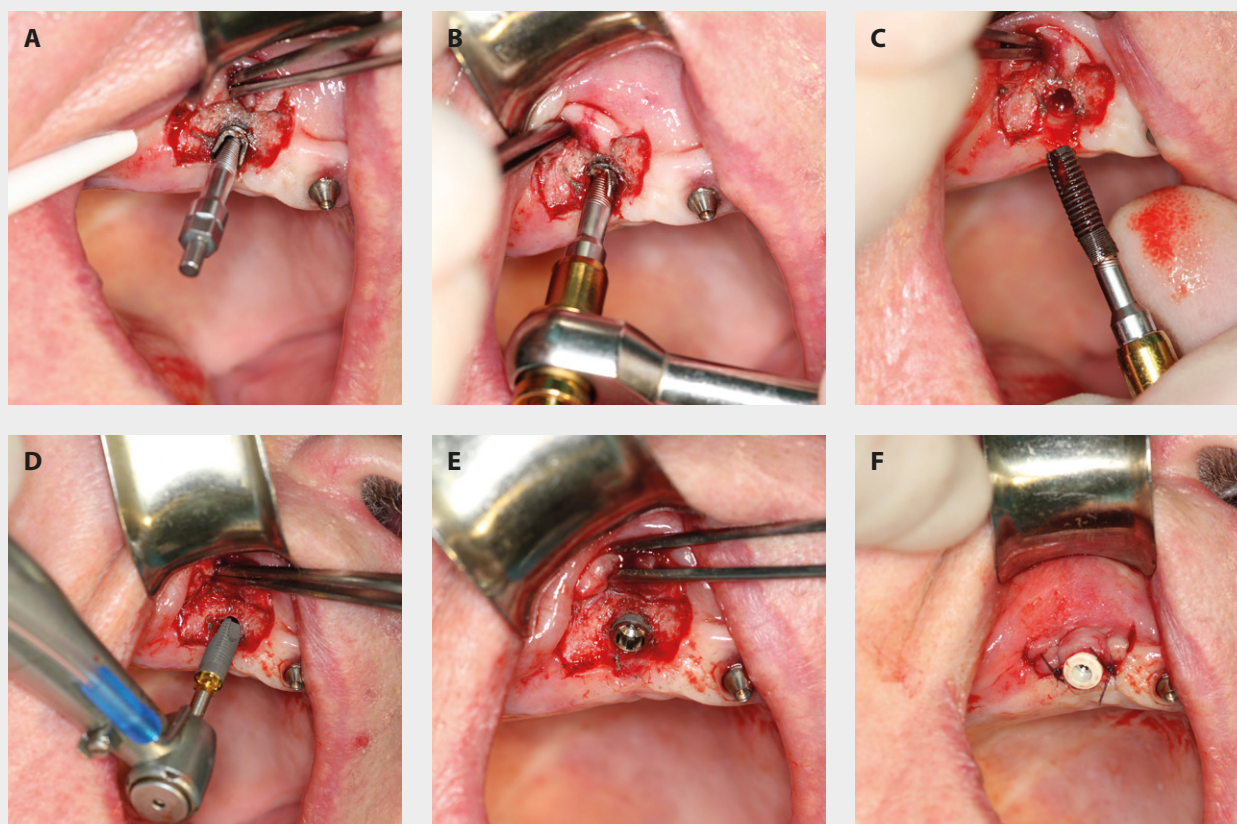
Inflammation and marginal bone loss at teeth, i.e. gingivitis and periodontitis, are considered as infectious and biofilm-mediated conditions. These are diagnosed by probing, where bleeding (BoP) indicates gingivitis and increased pocket depths (PPD) with bleeding (BoP) and bone loss indicate periodontitis. Removal of the biofilm and bacteria formation will resolve the inflammation/infection. In healthy periodontal conditions there are no signs of bleeding nor, in general, periodontal pockets.

Dental implants are placed in edentulous areas of the jaws during one or two surgical interventions. It is well documented that some marginal remodelling is occurring during the first year as a response to surgery, piercing of the mucosa and loading.<sup>16</sup> For a large group of implants, the average bone loss during the first year in function varies from 0.5 to 1.5 mm, mainly depending on the geometry of the implant.<sup>17</sup> After the first year in service, small changes of average marginal bone loss are observed over the following years of follow-up.<sup>17</sup> However, if making a frequency distribution of bone loss, some implants will show more bone loss than other implants.<sup>18</sup> There are many reasons for further marginal bone loss after the first year of function, such as physiological atrophy after tooth extraction, non-optimal surgery and prosthetic design, overload, thin bone, soft bone, cement residues just to mention a few. Thus, well-functioning dental implants can show non-infectious marginal bone resorption. For this reason, a zero-tolerance approach to bleeding, pocket depths and some marginal bone loss seems questionable.

### PERIODONTAL INDICES AT IMPLANTS

In analogy with teeth, the idea of using a dental probe at implants is to identify “affected” implants based on the presence of any BoP and PPDs deeper than 4 mm, which in combination with any radiographic bone loss would indicate disease. When reviewing the literature, it is evident that BoP may be detected at a majority of well-functioning dental implants.<sup>19</sup> Similarly, PPDs over 4 mm are frequent at healthy implants since the depth of the soft tissue tunnel is of course depending on the thickness of the mucosa and how deep the implant was placed.<sup>19</sup> As discussed above, most implants will show some bone loss over time as results of many other factors than biofilm-mediated resorption. A review of the literature concluded that;<sup>19</sup>

1. Probing pocket depth values of >4 mm at dental implants cannot be seen as a sign of pathology or an alarming signal regarding the conditions of the peri-implant tissues.
2. An increase of probing pocket depth values over time is not necessarily associated with loss of supporting bone around dental implants. Therefore, probing does not appear to be a reliable tool for the assessment of peri-implant marginal soft- and hard-tissue conditions.
3. From a biomaterial science point of view, osseointegration is a foreign-body reaction. As a consequence, bleeding on probing often reflect the nature of the tissue-implant interface and therefore does not appear to be a predictor for future loss of tissue support.



**Figure 3:** Showing atraumatic removal and replacement of a fractured AstraTech implant. (A) Removal tool applied. (B) Implant unscrewed with hand wrench. (C) Implant removed from intact socket. (D) Placement of a Neoss ProActive implant. (E) Implant in place. (F) Healing abutment and sutures applied.

4. Hence, probing pocket depth and bleeding on probing cannot be considered to be reliable tools or monitoring peri-implant health and disease.
5. Radiographic evaluation of crestal bone levels over time seems to be the most reliable tool to identify those implants undergoing continuous bone loss and therefore in need of treatment.
6. A single episode of bone loss does not necessarily call for treatment unless associated with clear signs of inflammation, such as profuse bleeding/suppurative and discomfort at pressure/palpation.

#### TRUE PERI-IMPLANTITIS LESIONS

True peri-implantitis lesions do exist and constitutes a threat to the longevity of the implant due to rapid marginal bone loss. Characteristic symptoms are swelling, redness, pain and suppuration when palpating the peri-implant soft tissues in addition to the presence of rapid marginal bone loss. The pathology of the development of a peri-implantitis lesion is not well understood. It is likely that marginal bone resorption of any reasons may have provided conditions for a secondary infection with anaerobic bacteria, which in

turn accelerate the tissue damage. The treatment aims at resolving the infection, which can include the use of local antibacterial rinsing, general treatment with antibiotics and surgical exploration of the area. Removal of the implant should be considered. Implant failure is not a terminal event in contrast to losing a tooth as a new implant can be placed if sufficient amount of bone is present (Figure 3).

#### GUIDELINES FOR FOLLOW-UP OF IMPLANTS

Based on the current degree of knowledge, the most reasonable approach is that implant patients should be examined annually for presence of clinical problems.

The clinical examination should include palpation and pressure on the tissues surrounding the implant to ensure absence of discomfort and pain at palpation, absence of redness and swelling in the soft tissues, absence of evident suppuration.

Radiographs should be taken once a year during the first two-three years of function and thereafter at regular intervals (every two or three years, depending on the findings of the clinical examination) to monitor the crestal bone level stability.

It should be kept in mind that “disease” cannot be diagnosed based on a single radiograph.

Instead, a series of radiographs from different times of follow up is needed to decide whether a particular implant has progressive loss of marginal bone. Only significant progressive loss of marginal bone, as verified in a series of radiographs, in association with clinical signs of inflammation such as redness, swelling, bleeding and suppuration at palpation and pressure on the soft tissues (not at probing) should be considered indicative of an ongoing peri-implantitis process.

## CONCLUSIONS

It is concluded that periodontal indices are not reliable either for identifying peri-implant disease or for predicting future marginal bone loss and implant failure.

The long-term experiences with dental implants, presented in the literature, indicate that the presence of bleeding on probing, probing pocket depths deeper than 4 mm and some marginal bone loss seem to reflect normal conditions of well-functioning dental implants in most of the cases, bearing in mind that healing of dental implants is the result of a foreign body reaction.

Therefore, the routine use of probing pocket depth and bleeding on probing assessments certainly lead to over-diagnosis and over-treatment of assumed biofilm-mediated peri-implantitis lesions.

## REFERENCES

- Buser D, Sennerby L, De Bruyn H. Modern implant dentistry based on osseointegration: 50 years of progress, current trends and open questions. *Periodontol* 2000. 2017;73:7-21
- Lindhe J, Meyle J. Peri-implant diseases: consensus report of the sixth European workshop on periodontology. *J Clin Periodontol*. 2008;35:282-285
- Lang NP, Berglundh T. Peri-implant diseases: where are we now? Consensus of the Seventh European Workshop on periodontology. *J Clin Periodontol*. 2011;38:178-181
- Ucer C, Wright S, Scher E, West N, Retzepi M, Simpson S, Slade K, Donos N. ADI guidelines. On peri-implant monitoring and maintenance. 2013. [http://www.adi.org.uk/resources/guidelines\\_and\\_papers/peri-implant/](http://www.adi.org.uk/resources/guidelines_and_papers/peri-implant/)
- Giannobile WV, Lang NP. Are dental implants a panacea or should we better-strive to save teeth? *J Dent Res*. 2016;95:5-6
- Derks J, Hakansson J, Wennstrom JL, Klinge B, Berglundh T. Patient-reported outcomes of dental implant therapy in a large randomly selected sample. *Clin Oral Implants Res*. 2015;26:586-591
- Derks J, Hakansson J, Wennstrom JL, Tomasi C, Larsson M, Berglundh T. Effectiveness of implant therapy analyzed in a Swedish population: early and late implant loss. *J Dent Res*. 2015;94(S3):S44-S51
- Derks J, Schaller D, Hakansson J, Wennstrom JL, Tomasi C, Berglundh T. Effectiveness of implant therapy analyzed in a Swedish population: prevalence of peri-implantitis. *J Dent Res*. 2016;95:43-49
- Albrektsson T, Buser D, Sennerby L. Crestal bone loss and oral implants. *Clin Implant Dent Relat Res*. 2012;14:783-791
- Psaty BM, Weiss NS, Furberg CD, Koepsell TD, Siscovick DS, Rosendaal FR, Smith NL, Heckbert SR, Kaplan RC, Lin D, Fleming TR, Wagner EH. Surrogate end points, health outcomes, and the drug-approval process for the treatment of risk factors for cardiovascular disease. *JAMA*. 1999;282:786-790
- Fransson C, Lekholm U, Jemt T, Berglundh T. Prevalence of subjects with progressive bone loss at implants. *Clin Oral Implants Res*. 2005;16:440-446
- Jemt T, Sundén P, K Gröndahl. Changes of marginal bone level in patients with ‘progressive bone loss’ at Brånemark System implants: a radio-graphic follow-up study over an average of 9 years. *Clin Implant Dent Relat Res*. 2015;17:619-628
- Coli P, Sennerby L. Is peri-Implant probing causing over-diagnosis and over-treatment of dental implants? *J Clin Med*. 2019;8:1123.
- Donath K. Pathogenesis of bony pocket formation around dental implants. *J Dent Assoc S Afr*. 1992;47:204-208
- Albrektsson T, Dahlin C, Jemt T, Sennerby L, Turri A, Wennerberg A. Is marginal bone loss around oral implants the result of a provoked foreign body reaction? *Clin Implant Dent Relat Res*. 2014;16:155-165
- Oh TJ, Yoon J, Misch CE, Wang HL. The causes of early implant bone loss: myth or science? *J Periodontol*. 2002;73:322-333
- Laurell L, Lundgren D. Marginal bone level changes at dental implants after 5 years in function: a meta-analysis. *Clin Implant Dent Relat Res*. 2011;13:19-28
- Pikner SS, Gröndahl K, Jemt T, Friberg B. Marginal bone loss at implants: a retrospective, long-term follow-up of turned Brånemark System implants. *Clin Implant Dent Relat Res*. 2009;11:11-23
- Coli P, Christiaens V, Sennerby L, Bruyn H. Reliability of periodontal diagnostic tools for monitoring peri-implant health and disease. *Periodontol* 2000. 2017;73:203-217

# NeoGen PTFE membranes. A review of the published clinical and pre-clinical evidence

Herman Sahlin<sup>1</sup>, Christer Dahlin<sup>2,3</sup>

<sup>1</sup> Neoss, Gothenburg, Sweden

<sup>2</sup> Department of Biomaterials, Institute of Clinical Sciences, Sahlgrenska Academy, University of Gothenburg, Sweden

<sup>3</sup> Department of Oral, Maxillofacial Surgery and Research and Development, NU-Hospital Organisation, Trollhättan, Sweden

*This review of the published clinical and pre-clinical evidence on NeoGen membranes confirms successful clinical outcome when used for guided bone generation and verical ridge augmentation procedures. Furthermore, pre-clinical studies suggest increased soft tissue healing and less biofilm formation for NeoGen membranes as compared to d-PTFE membranes.*

## INTRODUCTION

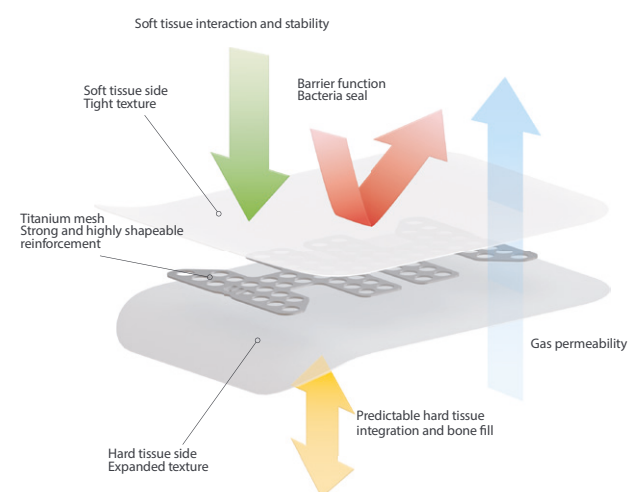
Guided bone regeneration (GBR) has been defined as the principle of using barrier membranes to exclude certain cell types such as rapidly proliferating epithelium and connective tissue, thus promoting the growth of slower-growing cells capable of forming bone.<sup>1,2</sup> The membranes used for GBR are resorbable or temporary implanted non-resorbable membranes surgically placed between the soft tissue (gingiva) and the jaw bone to act as a barrier and aid in the regenerative healing of bone defects in the jaw bone.

Non-resorbable membranes require additional surgical procedures to be removed after the augmentation procedure. However, they offer more predictable augmentation since the membrane stays intact and is more rigid than resorbable ones. Therefore, non-resorbable membranes made from polytetrafluoroethylene (PTFE) are more suitable for vertical ridge augmentations than resorbable membranes.

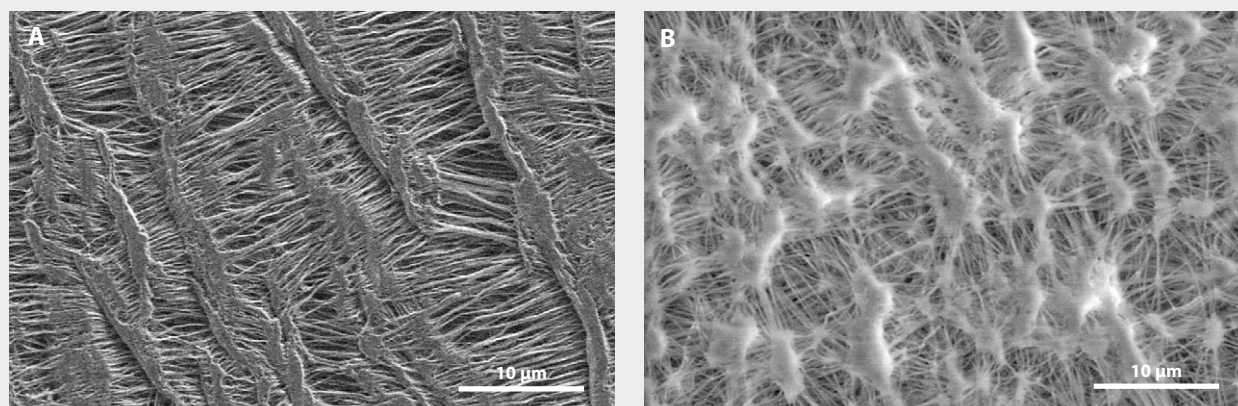
The evolution of PTFE membranes began in the late 1980s with W.L. Gore and Associates, Inc. developing an expanded PTFE membrane (e-PTFE). The Gore membranes integrated very well with the surrounding tissue but they were permeable to bacteria, making them vulnerable to exposure. In the 1990s a dense type of PTFE membrane (d-PTFE), designed to better withstand exposure, was de-

veloped. The e-PTFE membranes from Neoss (NeoGen PTFE membranes) are the third generation of non-resorbable membranes combining the handling and tissue interactions of e-PTFE with the enhanced barrier function offered by d-PTFE.

The aim of this review of peer-reviewed literature is to assess the current clinical and pre-clinical evidence on NeoGen PTFE membranes.



**Figure 1:** Design principle of the NeoGen PTFE membrane.



**Figure 2:** SEM pictures showing (A) the soft tissue side and (B) the bone side of the NeoGen e-PTFE membrane.

## MEMBRANE CONFIGURATION

### Design principle

The NeoGen membrane is a three layer membrane with a titanium reinforcement sandwiched between the outer and inner e-PTFE layers of the membrane. The titanium mesh is incorporated to make the membrane rigid and shapeable (Figure 1 and 5).

### Dual configuration PTFE

The NeoGen PTFE membrane have different design on the two sides. Both sides are composed of expanded PTFE (e-PTFE), where the expansion of the material creates a matrix of PTFE nodes and fibrils in a microstructure that can be varied in texture and porosity.

By changing the degree of expansion, the different biological requirements on the outside and the inside of the membrane can be addressed. Therefore, the outside of the membrane has a more closed structure to avoid bacterial

penetration and to facilitate soft tissue attachment, whereas the inside is more open to accommodate bone cell ingrowth (Figure 2).

### Titanium mesh

A titanium mesh is sandwiched between the two e-PTFE layers. The mesh configuration creates a strong and highly shapeable reinforcement that retains its shape throughout the healing period. A higher resistance to external forces is achieved by utilizing the mesh design instead of conventional finger-type reinforcement (Figure 3).

## ANTIBACTERIAL PROPERTIES

### Barrier function

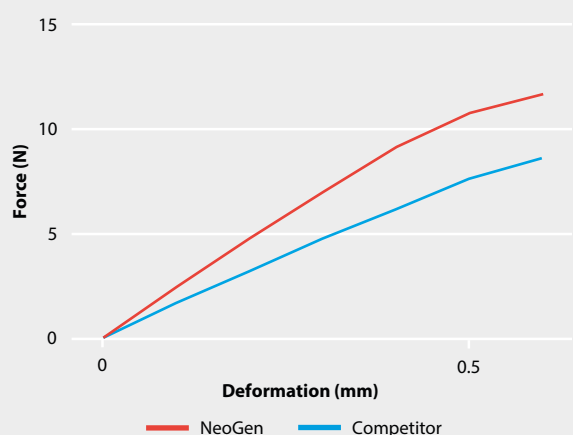
The barrier function of the membrane has been assessed by studying *Staphylococcus oralis* penetration through the membranes. The experimental setup consisted of two compartments separated only by a membrane. Bacteria was added in one compartment and measurements were done in both compartments over time. No bacteria penetrated the membrane during the 48-hour experiment, showing that the NeoGen membrane is impervious to bacteria.<sup>3</sup>

### Bacterial adhesion and biofilm formation in vitro


The same study also demonstrated less colonization of *S. oralis* on the membrane surface ( $p < 0.05$ ) and reduced build-up of biofilm ( $p < 0.05$ ) on NeoGen membranes than on the d-PTFE membrane (Cytoplast, Osteogenics, USA) used as control in the experiment.<sup>3</sup> This suggests that NeoGen has some antibacterial properties compared to d-PTFE.

### Bacterial adhesion and biofilm formation in vivo

To study if the in vitro results were also applicable in a clinical situation, a clinical study investigating bacterial adhesion on membranes exposed to the human oral cavity



**Figure 3:** Comparison of resistance to external forces between mesh reinforcement and finger-type reinforcement.

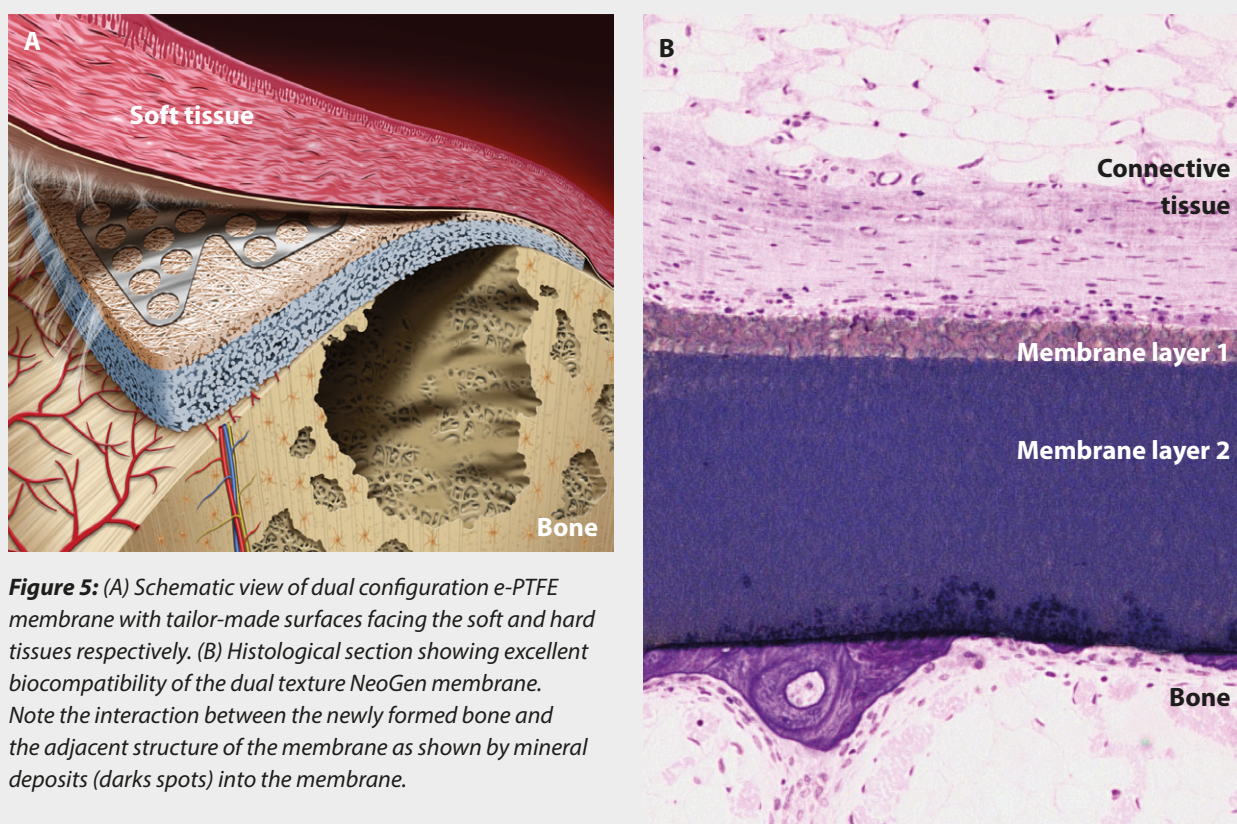


**Figure 4:** (A) SEM picture demonstrating a fibroblast attached to a NeoGen (e-PTFE) membrane surface. Note the healthy fibroblast morphology (spreading out on the surface). (B) SEM picture demonstrating a fibroblast attached to a d-PTFE membrane surface. The rounded cell shape indicates signs of apoptosis (non-viability).

for 4 and 24 hours. The amount of bacterial biomass were greater at 4 hours on the d-PTFE membrane than on the NeoGen membrane. The trend was similar, but no significant difference could be observed between the two membranes after 24 hours. The average thickness of the bacterial biofilm was also significantly greater on the d-PTFE membrane compared to d-PTFE at 4 hours but not at 24 hours.<sup>4</sup>

### CELL INTERACTIONS

Human gingival fibroblasts (HGF-1) were cultured on NeoGen and d-PTFE membranes. Higher cell numbers were found on NeoGen membranes than on d-PTFE membranes after 2 hours and 48 hours. Cells on d-PTFE membranes showed higher cell death compared to NeoGen membranes, as measured by lactate dehydrogenase (LDH) activity. SEM of the cells on the surfaces also showed



**Figure 5:** (A) Schematic view of dual configuration e-PTFE membrane with tailor-made surfaces facing the soft and hard tissues respectively. (B) Histological section showing excellent biocompatibility of the dual texture NeoGen membrane. Note the interaction between the newly formed bone and the adjacent structure of the membrane as shown by mineral deposits (dark spots) into the membrane.

differences in shape on adhering cells. Cells on NeoGen membranes had elongated cell protrusions and more spread-out cells closely adhering to the membrane surface whereas cells on the d-PTFE membranes had rounded, more compartmentalized shapes, indicating signs of apoptosis, i.e. non-viability of adhering cells (Figure 4).<sup>5</sup>

#### PRE-CLINICAL DATA

The effect of the NeoGen membrane on surrounding tissue during bone augmentation was evaluated in a rat femur model that evaluated histology and gene expression in the soft tissue above the membrane, the membrane itself, and the bone defect. The study compared NeoGen membranes with d-PTFE and treatment without a membrane (sham).<sup>6</sup>

Histological evaluation showed that both membranes promoted bone regeneration compared to sham, and that gene expression was similar in all groups in the underlying bone defect. In the soft tissue however, several differences were detected. NeoGen membranes promoted an attenuated inflammatory response (TNF- $\alpha$ ) and an enhanced molecular cascade for soft tissue healing (FGF-2 and VEGF) compared to d-PTFE membranes. In the membrane compartment, NeoGen membrane significantly up-regulated the genes associated with vascularization as well as bone and soft tissue healing (BMP-2, Coll1a1, FGF-2, and VEGF), while down-regulating the genes of pro-inflammatory cytokines (TNF- $\alpha$  and IL-6).<sup>6</sup>

The data show that the membrane is actively involved in the molecular pathways that are activated during GBR. The enhanced molecular cascade for soft tissue healing and the down-regulation of inflammatory response in the later stages seen for NeoGen membranes compared to d-PTFE membranes can be beneficial for soft tissue integration and clinical outcome.<sup>6</sup>

#### CLINICAL DATA

The published clinical evidence on NeoGen PTFE membranes consist of three articles reporting on more than 900 membranes, with clinical follow-up up to 5 years after membrane procedure.<sup>7–9</sup>

##### *Overall results*

GBR is a technique sensitive procedure, and the result is largely dependent on the lack of complications. Favorable treatment results are largely dependent on the absence of complications. Therefore complication rates are important to monitor.

In the NeoGen studies, the overall complication rate was 12–21%,<sup>7–9</sup> compared to 24–43% reported in the literature.<sup>10,11</sup> Of this, soft tissue complications amounted to

5–10%,<sup>7,8</sup> compared to 17–18% reported in the literature,<sup>12</sup> and membrane exposure rate was 7–11% for NeoGen<sup>7,8</sup> and 8–43% reported in the literature.<sup>10,11,13</sup>

It can be concluded that the complication rates seen for NeoGen membranes compares very well with the published literature. In addition it should be noted that the occurrence of a complication such as a membrane exposure doesn't automatically lead to a treatment failure. On the contrary, implants could be placed in all NeoGen membrane augmented sites (100%) and favorable augmentation results are often achieved also in sites with complications.

##### *Vertical ridge augmentation*

Two studies reported on vertical ridge augmentation with NeoGen membranes. The reported vertical defect reduction in these studies were 86–100%,<sup>8,9</sup> where 0% means no bone augmentation compared to initial situation and 100% means complete bone fill of the defect under the membrane. The published literature reports comparable values to be 78–96%.<sup>10,14</sup> This shows that NeoGen membranes performs at least as good as membranes reported in the literature in vertical ridge augmentation cases.

##### *Implant survival*

The true measurement on augmentation success is how well the implants that are eventually placed in the augmentation perform. Implants placed in sites augmented with NeoGen membranes were followed for up to 5 years and showed excellent results. The cumulative survival rates reported were 99.8–100%.<sup>7,8</sup> In comparison, the studies identified in the literature showed implant survival rates of 94.1–100%.<sup>13,15</sup>

#### CONCLUSIONS

This review of the published clinical and pre-clinical evidence on NeoGen membranes confirms successful clinical outcome when used for guided bone generation and vertical ridge augmentation procedures. Furthermore, pre-clinical studies suggest increased soft tissue healing and less bio-film formation for NeoGen membranes as compared to d-PTFE membranes.

## REFERENCES

1. Dahlin C, Sennerby L, Lekholm U, Linde A, Nyman S: Generation of new bone around titanium implants using a membrane technique: An experimental study in rabbits. *Int J Oral Maxillofac Implants.* 1989;4:19-25
2. Schenk RK, Buser D, Hardwick R, Dahlin C: Healing pattern of bone regeneration in membrane-protected defects: A histologic and histomorphometric study in the mandible of dogs. *Int J Oral Maxillofac Implants.* 1994;9:13-29
3. Trobos M, Juhlin A, Shah FA, Hoffman M, Sahlin H, Dahlin C. In vitro evaluation of barrier function against oral bacteria of dense and expanded polytetrafluoroethylene (PTFE) membranes for guided bone regeneration. *Clin Implant Dent Relat Res.* 2018;20:738-748
4. Turri A, Cergic E, Shah FA, Hoffman M, Omar O, Dahlin C, Trobos M. Early plaque formation on PTFE membranes with expanded or dense surface structures applied in the oral cavity of human volunteers. *Clin Exp Dent Res.* 2021;7:137-146
5. Trobos M, Juhlin A, Shah FA, Hoffman M, Johansson A, Sahlin H, Omar O, Dahlin C. Bacterial colonization and fibroblast cyto-compatibility of dPTFE and ePTFE GBR membranes. *Clin Oral implants Res.* 2017;28(S14):55
6. Omar O, Turri A, Sahlin H, Trobos M, Thomsen P, Dahlin C. Dual-layered non-resorbable PTFE membrane promotes a bidirectional molecular cross-talk with cells in both soft-tissue and bone defect compartments during GBR. *Osteology congress.* 2019:Poster 222
7. Hassfurth N, Hassfurth N, Pons-Kühnemann J, Howaldt H, Schaaf H. GBR using non-resorbable membranes and simultaneous implant placement. A comparative retrospective study. *Clin Oral Implants Res.* 2020;31(S20):244
8. Hassfurth N, Scheibelhut C, Hassfurth N, Pons-Kühnemann J, Howaldt H, Schaaf H. Vertical ridge augmentation with PTFE membranes and simultaneous implantation. A comparative study. *Clin Oral Implants Res.* 2021;32(S22):160
9. Poli PP, Mukhtadar AK, Souza FA, Maiorana C, Beretta M. Computer-guided implant placement associated with computer-aided bone regeneration in the treatment of atrophied partially edentulous alveolar ridges: A proof-of-concept study. *J Dent Sci.* 2021;16:333-341
10. Garcia J, Dodge A, Luepke P, Wang HL, Kapila Y, Lin GH. Effect of membrane exposure on guided bone regeneration: A systematic review and meta-analysis. *Clin Oral Implants Res.* 2018;29:328-338
11. Soldatos NK, Stylianou P, Koidou VP, Angelov N, Yukna R, Romanos GE. Limitations and options using resorbable versus nonresorbable membranes for successful guided bone regeneration. *Quintessence Int.* 2017;48:131-147
12. Lim G, Lin GH, Monje A, Chan HL, Wang HL. Wound Healing Complications Following Guided Bone Regeneration for Ridge Augmentation: A Systematic Review and Meta-Analysis. *Int J Oral Maxillofac Implants.* 2018;33:41-50
13. Elnayef B, Monje A, Gargallo-Albiol J, Galindo-Moreno P, Wang HL, Hernandez-Alfaro F. Vertical Ridge Augmentation in the Atrophic Mandible: A Systematic Review and Meta-Analysis. *Int J Oral Maxillofac Implants.* 2017;32:291-312
14. Merli M, Merli I, Raffaelli E, Pagliaro U, Nastri L, Nieri M. Bone augmentation at implant dehiscences and fenestrations. A systematic review of randomised controlled trials. *Eur J Oral Implantol.* 2016;9:11-32
15. Keestra JA, Barry O, Jong L, Wahl G. Long-term effects of vertical bone augmentation: a systematic review. *J Applied Oral Sci.* 2016;24:3-17

# Vertical and horizontal guided bone regeneration (GBR) using a Ti-reinforced non-resorbable e-PTFE membrane and simultaneous implant placement. A retrospective study

Nicolas Hassfurther<sup>1,2</sup>, Norbert Hassfurther<sup>1</sup>

<sup>1</sup> Private Practice, Wettenberg, Germany

<sup>2</sup> Faculty of Medicine, Justus Liebig University Giessen, Giessen, Germany

*This retrospective chart review of 903 sites treated according to a GBR protocol with simultaneous implant placement using NeoGen PTFE membranes and Neoss ProActive implants showed an implant survival rate of 99.8% after a follow-up of up to 5 years after membrane removal. Vertical ridge augmentation cases showed a mean bone fill of 86% Membrane related soft tissue complications occurred in 11% of the cases.*

## INTRODUCTION

Guided bone regeneration (GBR) is a treatment concept for bone augmentation where a membrane is placed between the soft tissue and the bone, to obstruct the soft tissue from growing into the bone defect. The membrane creates a space where the bone forming cells can generate new bone without the interference from soft tissue cells.

GBR can be performed in numerous ways: with resorbable or non-resorbable membranes, with or without grafting material, with or without structural reinforcement, in a staged approach or simultaneous with implant placement.<sup>2</sup>

The aim of the study was to retrospectively study the clinical outcome of a GBR procedure using a Ti-reinforced non-resorbable e-PTFE membrane and autogenous bone material with simultaneous implant placement. Results from this study cohort has previously been published.<sup>1,2</sup>

## MATERIALS AND METHODS

### Study design

This retrospective study reports on the clinical outcome of consecutive patients treated in the same clinic by one surgeon (NoH) using a surgical protocol where a guided bone regeneration (GBR) procedure using autogenous bone

material and a non-resorbable e-PTFE membrane (NeoGen Ti-Reinforced PTFE Membrane, Neoss, Gothenburg, Sweden) was performed at time of implant placement.

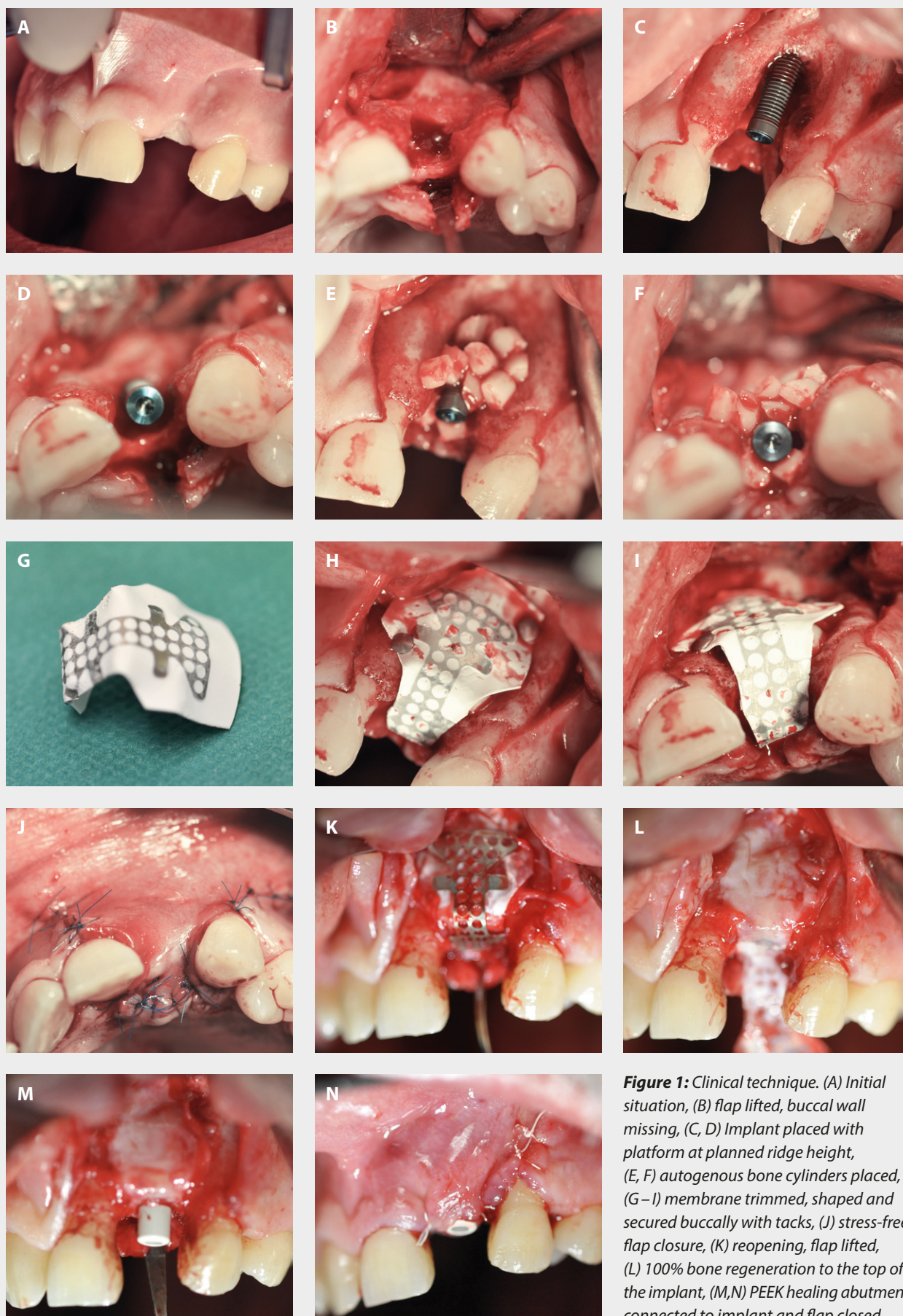
All patients that underwent the clinical procedure were deemed appropriate through clinical and radiographic examination before treatment. The patients were informed of the procedures and gave their written consent before treatment.

All study data was collected through a retrospective chart review. All collected data was part of the patients files, therefore no additional treatments were performed as part of this study. The retrospective data collection was conducted in accordance with the World Medical Association Declaration of Helsinki and approved by the Ethics Committee of the Department of Medicine of the Justus Liebig University Giessen (AZ 222/19).

### Treatment protocol

Antibiotic treatment was commenced the evening before surgery and lasted for 5 days. All surgeries were performed under local anesthesia.

A full thickness flap with releasing incisions was opened and the implant site was prepared (Figure 1B).



Implant osteotomies were drilled according to the manufacturer's guidelines to achieve good primary stability.

Autogenous bone chips were collected during preparation of the implant osteotomies using a bone collecting device connected to the suction system.

One or more dental implants (Neoss ProActive Straight, Neoss, Sweden) were placed with the implant-abutment connection at planned future bone level and a cover screw was connected (Figure 1C–D).

In larger defect cases, autogenous bone cylinders were used together with the autogenous bone chips to accelerate regeneration and to act as space fillers (Figure 1E–F). The bone cylinders (height up to 5 mm) were harvested from the oblique line of the mandible in the molar region using a 3.4 mm trephine drill. In smaller defect cases, only autogenous bone chips were used. No additional bone substitutes were used.

A Ti-reinforced e-PTFE membrane (NeoGen Ti-Reinforced PTFE Membrane, Neoss, Gothenburg, Sweden) was trimmed, shaped (Figure 1G), and fitted at the surgical site and secured buccally using membrane tacks (Figure 1H–I). A stable membrane configuration was achieved using the implants as tent posts.

Stress free flap closure was achieved by releasing the periosteum on the buccal side (Figure 1J).

The augmented sites were typically allowed to heal for 4–7 months, depending on clinical situation. After the healing period, second stage surgery was performed. A mid-crestal incision with releasing incisions was used. The flap was lifted to expose the membrane (Figure 1K) and the membrane was removed. If needed, excess bone on top of the cover screw (Figure 1L) was removed to get access to the implant. PEEK healing abutments (Neoss, Sweden) were connected to the implants for transgingival healing (Figure 1M) and the flap was closed (Figure 1N).

The definitive prostheses were delivered 0–18 months (average 2.8 months) after membrane removal.

#### Baseline parameters

Baseline parameters (age, gender, smoking habits, diabetes, tooth status, defect type, type of bone transplant, bone quality, and primary stability) were retrieved from the patient files (Table 1).

#### Follow-up

All information on membrane complications, such as infection and membrane exposure, were compiled from the patient records. The influence of the recorded baseline parameters on complication rate was evaluated.

Parameter	Group	n	%
Gender	Female	322	50.1
	Male	321	49.9
Age	10–19	11	1.7
	20–29	19	3.0
	30–39	37	5.8
	40–49	77	12.0
	50–59	207	32.2
	60–69	189	29.4
	70–79	95	14.8
	80–89	7	1.1
	90–99	1	0.2
Smoker	No	496	77.1
	Yes	147	22.9
Diabetes	No	628	97.7
	Yes	15	2.3
Defect type	Fenestration defect	36	5.6
	Intra-alveolar defect	12	1.9
	Horizontal defect < 50%	217	33.8
	Horizontal defect > 50%	254	39.5
	Horizontal defect buccal and oral	24	3.7
	Vertical defect ≤ 3 mm	62	9.6
	Vertical defect > 3 mm	38	5.9
Tooth status	Edentulous jaw	29	4.5
	Free-end gap	166	25.8
	Single-tooth gap, anterior	131	20.4
	Single-tooth gap, posterior	133	20.7
	Interdental gaps, anterior	49	7.6
	Interdental gaps, posterior	121	18.8
	Reduced residual dentition	14	2.2
Type of bone transplant	None	4	4.0
	Bone chips	34	34.3
	Bone cylinders	12	12.1
	Bone chips + Bone cylinders	49	49.5
Bone quality	D1	120	18.7
	D2	194	30.2
	D3	150	23.3
	D4	179	27.8
Primary Stability	High (> 30 Ncm)	448	69.7
	Poor (8–30 Ncm)	154	24.0
	Spinner (< 8 Ncm)	39	6.1
	None (extraaxial movement)	2	0.3

**Table 1:** Baseline parameters

The latest time-point registered in the patient's file was used for the implant follow-up. Implant follow-up time was calculated from time of membrane removal.

#### Vertical ridge augmentation

In sites where vertical ridge augmentation was performed ( $n = 95$ ), the vertical bone level was assessed at time of surgery and at membrane removal. The change in bone level as well as the percentage bone gain was assessed (0% = no bone gain, 100% = bone regenerated to level of implant platform). One implant from each augmentation was chosen for analysis.

Parameter	All sites	Vertical ridge augmentation sites
Number of implants	903	95
Early exposure rate	7%	11%
Infection rate	4%	10%
Overall membrane complication rate	11%	21%
Implant restorability rate	100%	100%

**Table 2:** Membrane complication rates**RESULTS***Overall outcome*

The chart review identified 903 sites where a GBR procedure using a NeoGen PTFE membrane was performed simultaneous with implant placement. Vertical ridge augmentation was performed in 95 of these sites.

Eleven percent (11%) of the membrane sites experienced complications that required intervention, 7% were early exposures and 4% were infections. The corresponding complication rates in vertical ridge augmentations was slightly increased, 11% and 10% respectively (Table 2). Although some membranes had to be removed early, all placed implants could be restored. One implant failed after 2 years, resulting in an cumulative implant survival rate of 99.8% (Table 3).

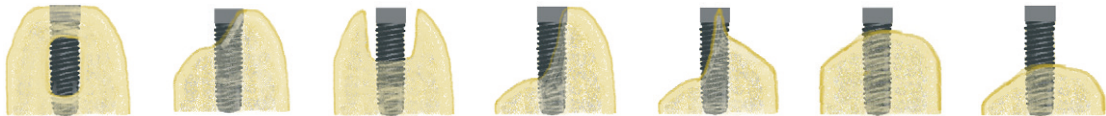
Time interval	Implants	Failed	Withdrawn / Not followed	CSR
Insert. – 1 year	903	0	332	100%
1 – 2 years	571	0	139	100%
2 – 3 years	432	1	194	99.8%
3 – 4 years	237	0	166	99.8%
4 – 5 years	71	0	67	99.8%
5 years	4	–	–	–

**Table 3:** Life table analysis. Dental implant survival.*Vertical ridge augmentation*

The mean vertical defect size at surgery was  $3.9 \pm 2.3$  mm, measured with the implant as reference. After augmentation the mean marginal bone level was  $0.5 \pm 0.9$  mm. This represents a mean bone gain of 87.5%. Bone regeneration up to or above the implant platform was achieved in 51% of the sites.

*Evaluation of risk factors*

For three parameters (defect type, tooth status and smoking) there was a significant impact on complication rate. The impact of each parameters as well as a proposed risk classification is given in Table 4. For all other investigated parameters, there was no significant difference in complication rate between groups, and thus not considered risk factors for the procedure.

	Low risk		Decreased risk		Increased risk		High risk
Defect type							
	Fenestration defect	Horizontal defect < 50% of the implant length	Intra-alveolar defect	Horizontal defect > 50% of the implant length	Horizontal defect buccal and oral	Vertical defect ≤ 3 mm	Vertical defect > 3 mm
Risk ratio	0.4	0.8	0.9	1.2	1.6	1.6	2.4
Tooth status	Edentulous jaw	Free-end gap	Single-tooth gap posterior region	Interdental gaps posterior region	Single-tooth gap anterior region	Interdental gaps anterior region	Reduced residual dentition
Risk ratio	0.5	1.0	1.1	1.3	1.3	1.6	1.7
Smoking	Non-smoker					Smoker	
Risk ratio	0.9					1.4	
Examples: Based on an average risk of 11% in the population	A non-smoking patient with a small horizontal defect in the toothless-jaw has a risk of membrane complication of 4%: (11% × 0.8 × 0.5 × 0.9 = 4%)  A smoking patient with a large vertical defect with reduced residual dentition has a risk of membrane complication of 63%: (11% × 2.4 × 1.7 × 1.4 = 63%)						

**Table 4:** Risk classification for e-PTFE membrane complication in relation to average risk.

## DISCUSSION

In the present study, membrane complications occurred in 11% of the membrane sites. This is well in line with what is reported in a recent systematic review by Lim et al that reported an average complication rate of 17.6% for non-resorbable membranes and 18.3% for resorbable membranes.<sup>3</sup>

Membrane complications do occur, but it is not an event that automatically result in a failed treatment. On the contrary, all complications in the present study were resolved and all implants could be restored. This is in line with the results of Lim et al. They reported that the majority of studies in their systematic review achieved complete healing of the sites that had experienced complications without significant impact on the bone augmentation procedure.<sup>3</sup>

The risk classification given in Table 4, shows how different parameters influence the risk of complications. It should not be used as a formula to calculate exact risk ratios, but more as a tool to see how combining different indications and parameters can lead too higher risk and thereby identifying if a patient is at risk for the procedure.

It is concluded that guided bone regeneration (GBR) using the Ti-reinforced NeoGen PTFE membrane and simultaneous implant placement is a reliable and time efficient treatment in cases where bone augmentation is needed for implant placement.

## REFERENCES

1. Dahlin C, Linde A, Gottlow J, Nyman S. Healing of bone defects by guided tissue regeneration. *Plast Reconstr Surg*. 1988;81:672-676
2. Retzepi M, Donos N. Guided Bone Regeneration: biological principle and therapeutic applications. *Clin Oral Implants Res*. 2010;21:567-576
3. Lim G, Lin GH, Monje A, Chan HL, Wang HL. Wound Healing Complications Following Guided Bone Regeneration for Ridge Augmentation: A Systematic Review and Meta-Analysis. *Int J Oral Maxillofac Implants*. 2018;33:41-50



